

**COMMON FINDINGS IN ABDOMINO-PELVIC COMPUTED TOMOGRAPHY
EXAMINATIONS IN NIGERIAN ADULTS (A CASE STUDY OF THE UNIVERSITY
OF BENIN TEACHING HOSPITAL)**



BY

IYENGUMWENA VERA OSATOHAMWEN

BMS2101832

DEPARTMENT OF RADIOGRAPHY

SCHOOL OF BASIC MEDICAL SCIENCES

UNIVERSITY OF BENIN JUNE, 2025

TITLE PAGE

**COMMON FINDINGS IN ABDOMINO-PELVIC COMPUTED TOMOGRAPHY
EXAMINATIONS IN NIGERIAN ADULTS (A CASE STUDY OF THE UNIVERSITY
OF BENIN TEACHING HOSPITAL)**

BY

IYENGUMWENA VERA OSATOHAMWEN

BMS2101832

**A PROJECT WORK SUBMITTED IN PARTIAL FULFILMENT OF THE
REQUIREMENTS FOR THE AWARD OF BACHELOR OF SCIENCE DEGREE IN
RADIOGRAPHY**

DEPARTMENT OF RADIOGRAPHY

SCHOOL OF BASIC MEDICAL SCIENCES

UNIVERSITY OF BENIN.

SUPERVISOR: AKPOBASAHAN E.A. (Dr.)

JUNE, 2025

DECLARATION

I declare that:

This project work is based on a study carried out by me in the Department of Radiography, School of Basic Medical Science, University of Benin under the supervision of Dr. Akpobasahan E.A. All ideas and views are a product of my personal research, efforts and all references to works of other have been fully acknowledged.

Iyengumwena Vera Osatohamwen

Project Researcher

CERTIFICATION

This is to certify that this project work was carried out by Iyengumwena Vera Osatohamwen with matriculation number (BMS2101832) of the Department of Radiography, School of Basic Medical Science, University of Benin, Benin City, Edo State, Nigeria.

NAME OF SUPERVISOR _____

SIGNATURE _____

DATE. _____

NAME OF EXTERNAL SUPERVISOR _____

SIGNATURE _____

DATE _____

NAME OF HEAD OF DEPARTMENT _____

SIGNATURE _____

DATE. _____

DEDICATION

This work is dedicated to God Almighty, my heavenly father for his love, support and strength through it all. And to my entire family for their love and support through it all, I am grateful.

ACKNOWLEDGEMENT

My profound gratitude goes to God Almighty for his help, mercies, loving kindness and faithfulness to me through it all.

Special thanks goes to my supervisor Dr. E.A. Akpobasahan for her words of encouragement, support, corrections and guidance in the course of completing this project work. I also want to specially acknowledge my HOD, Prof. Mrs. F.O. Igbinedion, and my daddy Dr. G.E. Okungbowa and other lecturers of the Department of Radiography, University of Benin who have impacted me, I am grateful.

My heart also goes out to my entire family, my daddy of blessed memory, my big mummy, my mummy, my brothers, my sisters, my cousins, my sisters, my Aunties and my Uncles, I am grateful for the love and mighty support through it all.

Special thanks to my course mates, friends and my supernatural relationships, too many to mention, I am grateful for all your support, words of encouragement, your prayers and for also being a part of my journey and making it a memorable one, I am grateful, God bless you all.

TABLE OF CONTENTS

TITLE PAGE	1
DEDICATION	5
ACKNOWLEDGEMENT	6
TABLE OF CONTENTS	7
LIST OF FIGURES	10
ABSTRACT	11
CHAPTER ONE	12
INTRODUCTION	13
1.1 BACKGROUND OF THE STUDY	13
1.2 STATEMENT OF THE PROBLEM	14
1.3 AIM AND OBJECTIVE OF THE STUDY	16
1.3.1 AIM	16
1.3.2 OBJECTIVE	16
1.4 SIGNIFICANCE OF THE STUDY	16
1.5 RESEARCH QUESTION	17
1.6 HYPOTHESIS	18
1.7 SCOPE OF THE STUDY	18
1.8 DEFINITION OF KEY TERMS	19
CHAPTER TWO	20
2.1 CONCEPTUAL REVIEW	20
2.1.1 INTRODUCTION	20
2.1.2 ANATOMY OF THE ABDOMEN AND PELVIS	21

2.1.4 Abdominal And Pelvic Imaging Procedure	24
2.1.5 Indications for Abdomino-Pelvic Computed Tomography Scans	28
2.1.6 Common Pathologies Detected on Abdomino-Pelvic Computed Tomography	28
2.1.7 Importance of Understanding the common findings in Computed Tomography examination.	29
2.1.8 Regional and Demographic Considerations	29
2.2 EMPIRICAL REVIEW	30
CHAPTER THREE	34
3.1 Introduction	34
3.2 Research Setting	34
3.3 Study Design	34
3.4 Target Population	34
3.5 Sampling Technique and Sample Size	35
3.6 Instrument for Data Collection	36
3.7 Validity of Instrument	36
3.8 Reliability of Instrument	36
3.9 Method of Data Collection	37
3.10 Method of Data Analysis	37
3.11 Ethical Consideration	37
CHAPTER FOUR	38
DATA PRESENTATION AND ANALYSIS	38
4.1 Introduction	38
4.2 Socio-Demographic Characteristics of Patients	38
4.3 Clinical Indications for Abdomino-Pelvic CT Scans	42

4.4 Radiological Findings	45
4.5 Summary of Quantitative Results	49
CHAPTER FIVE	50
DISCUSSION, SUMMARY OF DISCUSSION, CONCLUSION AND RECOMMENDATIONS	50
5.1 DISCUSSION	50
5.2 SUMMARY OF DISCUSSION	54
5.3 CONCLUSION	55
5.4 RECOMMENDATIONS	57
APPENDIX I: Data capture sheet	60
APPENDIX II: Ethical Approval Letter	61
REFERENCES	62

LIST OF FIGURES

Figure 1: Abdominopelvic regions	22
Figure 2: Bones of the pelvic regions	23

ABSTRACT

Abdomino-pelvic computed tomography (CT) is one of the most important diagnostic tools in modern radiology, providing detailed cross-sectional images that aid in the evaluation of a wide range of abdominal and pelvic diseases. However, in Nigeria, there remains limited documentation of the common computed tomography findings in adults, which affects evidence-based diagnosis and healthcare planning. This study assessed the common findings observed in abdomino-pelvic computed tomography examinations among adult patients at the University of Benin Teaching Hospital (UBTH), Benin City, Nigeria.

A retrospective study design was adopted, reviewing 105 abdomino-pelvic computed tomography reports of adult patients aged 18 years and above who were examined between May 2024 and May 2025. Data were collected using a structured extraction sheet and analyzed with the Statistical Package for the Social Sciences (SPSS) version 27. Descriptive statistics summarized demographic characteristics, clinical indications, and computed tomography findings, while inferential statistics assessed associations between variables at a significance level of $p < 0.05$.

The findings revealed a slight male predominance (55.2%) and that most patients (47.6%) were aged 41–60 years. The leading clinical indications for computed tomography were abdominal pain or distension (17.1%), suspected malignancy (16.2%), and trauma (6.7%). Liver-related abnormalities were the most common radiological findings, with hepatomegaly (22.9%), liver cirrhosis (7.6%), and primary liver cell carcinoma (7.6%) being predominant. Fluid collections such as ascites and pleural effusion were also notable (10.5% each), while only 3.8% of the scans were normal.

This study concludes that abdomino-pelvic computed tomography plays a crucial role in diagnosing hepatic and oncologic diseases, which remain the leading causes of abdominal morbidity among Nigerian adults. The results underscore the need for improved hepatic disease screening, enhanced computed tomography infrastructure, and data-driven clinical practices in tertiary healthcare settings.

Keywords: Computed Tomography, Abdomino-pelvic Imaging, Liver Pathology, Hepatomegaly, Nigeria, UBTH.

CHAPTER ONE

INTRODUCTION

1.1 BACKGROUND OF THE STUDY

The application of computed tomography (CT) in the realm of medical imaging has transformed the diagnostic environment across numerous medical disciplines (Hsieh & Flohr, 2021), with abdominal and pelvic imaging being among the most commonly requested type. Abdomino-pelvic computed tomography is essential for its capacity to deliver high-resolution cross-sectional images, making it crucial for assessing a diverse range of conditions that impact abdominal and pelvic organs, including the liver, kidneys, pancreas, bowel, bladder, reproductive organs, and vascular systems. It is instrumental in the diagnosis of acute abdominal pain, trauma, cancers, infections, and inflammatory diseases, in addition to its role in follow-up assessments and preoperative planning (Morani et al., 2020).

In numerous developed nations, comprehensive research and population-based data have enhanced the understanding of the epidemiology and radiologic findings associated with abdomino-pelvic diseases. Nevertheless, in several developing countries, such as Nigeria, there exists a notable scarcity of this type of data. This deficiency in localized radiologic epidemiology results in a considerable knowledge gap, particularly affecting clinical decision-making, resource allocation, and the formulation of health policies (Mollura et al., 2020). There is an urgent requirement for region-specific studies to gain a deeper insight into the common findings in abdomino-pelvic pathologies, particularly among adult populations, where the incidence of both communicable and non-communicable diseases is increasing.

Nigeria, recognized as the most populous nation in Africa, showcases a wide array of diseases shaped by various factors including urbanization, dietary practices, genetic factors,

environmental influences, and access to healthcare. In tertiary healthcare institutions like the University of Benin Teaching Hospital (UBTH), there is an increasing reliance on computed tomography services to facilitate precise diagnoses and inform treatment decisions. Gaining an understanding of these patterns can yield insights into the prevalent disease conditions in the area, improve diagnostic precision and assist clinicians in the effective utilization of imaging resources. Moreover, the growing availability of computed tomography imaging in Nigerian medical facilities aligns with a surge in non-communicable diseases such as cancers, metabolic syndromes, and vascular diseases, in addition to infectious diseases like tuberculosis and HIV/AIDS, which may present significant abdominal symptoms. Documenting the distribution, frequency, and characteristics of computed tomography findings in this context not only enhances clinical awareness but also enables radiologists and referring physicians to customize imaging protocols and diagnostic priorities according to local disease trends. The University of Benin Teaching Hospital (UBTH), as a prominent referral center in southern Nigeria, caters to a large and varied patient population, rendering it an ideal site for such research. By examining abdomino-pelvic computed tomography findings in adult patients at the University of Benin Teaching Hospital (UBTH), this study seeks to identify the dominant disease findings, evaluate the demographic distribution of these conditions, and contribute essential data to the expanding corpus of Nigerian radiologic literature.

1.2 STATEMENT OF THE PROBLEM

Abdomino-pelvic conditions represent a significant portion of clinical presentations among adult patients in Nigeria, encompassing a range of disorders from gastrointestinal and genitourinary issues to neoplastic, infectious, inflammatory, and traumatic conditions (Adeyanju, 2022). Nevertheless, in Nigeria, particularly within tertiary healthcare facilities like the University of

Benin Teaching Hospital (UBTH), there exists a scarcity of local data that systematically records the common findings of abdomino-pelvic computed tomography in adult patients (Ezechukwu, 2020). This absence of empirical data poses a considerable obstacle to evidence-based medical practice, particularly in resource-constrained environments (Valtis et al., 2016). Clinicians frequently find themselves compelled to make diagnostic and treatment choices based on generalized or outdated information, which may not accurately represent the current or region-specific disease burden. In the absence of a thoroughly documented computed tomography findings, it becomes challenging to identify prevalent or emerging pathologies, recognize potential epidemiological shifts in disease presentation, or evaluate the effects of socioeconomic and environmental changes on health outcomes (Parham et al., 2015).

Furthermore, demographic elements such as age and gender, along with clinical reasons for conducting computed tomography scans, are infrequently examined in relation to actual radiological results. The lack of this connection hinders the capacity of radiologists and referring doctors to make predictive diagnostic assessments and undermines the effectiveness of healthcare provision. In light of the growing demand for sophisticated imaging and the escalating financial strain on patients in Nigeria, it is crucial to ensure that the application of computed tomography scans is justified, data-informed, and optimized for patient advantage (Adekunle et al., 2024). In an institution like the University of Benin Teaching Hospital (UBTH), which acts as a referral center for a vast and varied patient demographic, comprehending the trends of abdomino-pelvic computed tomography findings is not only academically significant but also clinically vital (Goyal, 2024). The neglect to investigate and record these trends leads to persistent deficiencies in diagnostic precision, clinical decision-making, and resource allocation (Sutton et al., 2020). Consequently, there is a strong necessity for a systematic assessment of

computed tomography scan data to identify the common abdomino-pelvic pathologies among adult patients and to inform clinical and radiological best practices in the University of Benin Teaching Hospital (UBTH) and comparable facilities throughout Nigeria.

1.3 AIM AND OBJECTIVE OF THE STUDY

1.3.1 AIM

This study aims to assess the common findings in abdomino-pelvic computed tomography imaging amongst adult in the University of Benin Teaching Hospital.

1.3.2 OBJECTIVE

The objectives of this research are as follows:

- To ascertain the frequency and distribution of abdomino-pelvic computed tomography findings among adult patients at UBTH.
- To recognize the common pathological conditions identified through abdomino-pelvic computed tomography scans along with their demographic variations, including age, sex, and clinical presentation.

1.4 SIGNIFICANCE OF THE STUDY

The growing prevalence of abdomino-pelvic diseases among adult populations in Nigeria highlights the pressing necessity for precise, timely, and data-informed diagnostic methods. Computed Tomography (CT) stands as one of the most sophisticated imaging techniques currently available, providing intricate cross-sectional images of internal organs and structures.

Its role in assessing abdomino-pelvic disorders is crucial; however, the absence of extensive local data regarding the findings of computed tomography findings in adult Nigerian populations hinders the complete optimization of this diagnostic resource in clinical settings. This research aims to address that deficiency through a targeted case study at the University of Benin Teaching Hospital (UBTH), one of Nigeria's premier tertiary healthcare institutions. To begin with, the outcomes of this research will act as a vital epidemiological reference for recognizing the most common abdomino-pelvic conditions diagnosed through computed tomography imaging in Nigerian adults. Such data is critical for radiologists, physicians, and healthcare managers in customizing diagnostic protocols, enhancing clinical decision-making, and executing targeted interventions for the prevalent conditions. Furthermore, the study will aid in promoting the judicious use of computed tomography imaging by linking clinical indications with actual radiological results. This connection can assist in minimizing unnecessary radiation exposure, reducing healthcare expenses, and improving patient safety. It will also help referring clinicians comprehend when computed tomography scans are most likely to provide diagnostically valuable information. Moreover, by examining demographic factors such as age and gender in relation to computed tomography findings, the study will provide insights into diseases specific to the population. This information can guide public health initiatives and clinical education, ensuring that diagnostic and treatment strategies are more aligned with the local disease landscape.

1.5 RESEARCH QUESTION

- What are the common findings in abdomino-pelvic computed tomography (CT) imaging amongst adult patients at the University of Benin Teaching Hospital and how do these

findings relate to the demographic characteristics and clinical indications for imaging of the patients?

- What are the most commonly diagnosed abdomino-pelvic pathologies identified in computed tomography among adult patients at UBTH?

1.6 HYPOTHESIS

Null Hypothesis(H⁰): There is no significant association between demographic characteristics (age, sex) or clinical indications and the patterns of abdomino-pelvic computed tomography findings amongst adult patients at the University of Benin Teaching Hospital.

Alternative Hypothesis(H¹): There is a significant association between demographic characteristics (age, sex) or clinical indications and the patterns of abdomino-pelvic computed tomography findings amongst adult patients at the University of Benin Teaching Hospital.

1.7 SCOPE OF THE STUDY

This research focuses on assessing the common findings amongst adult patients who went through abdomino-pelvic computed tomography (CT) examinations at the University of Benin Teaching Hospital (UBTH) in Benin City, Edo State, Nigeria. The study is confined to adult patients aged 18 years and older who were referred for abdomino-pelvic computed tomography scans during a specified retrospective time frame (to be established based on available records e.g, six months to one year) depending on the availability of cases and the institution approval.

1.8 DEFINITION OF KEY TERMS

1. **Computed Tomography (CT):** A non-invasive medical imaging method that employs X-ray beams and computer processing to generate detailed cross-sectional images of the body, facilitating the assessment of internal structures such as bones, organs, and blood vessels.
2. **Abdomino-Pelvic Region:** The anatomical region that includes the abdominal and pelvic cavities. This area contains essential organs like the liver, spleen, pancreas, kidneys, intestines, bladder, reproductive organs, and their associated blood vessels and lymphatics.
3. **Computed Tomography Observations:** Radiological observations or diagnostic outcomes derived from computed tomography scan images, these findings may encompass normal structures, abnormalities, pathological changes, or incidental lesions identified during the scan.
4. **Common Findings:** The distribution, frequency, and types of radiological abnormalities noted within a specific population or patient group over a defined period.
5. **Adult Nigerian Population:** Refers to individuals aged 18 years and older who are citizens or residents of Nigeria. In this context, it specifically relates to adult patients receiving computed tomography imaging at UBTH.

CHAPTER TWO

LITERATURE REVIEW

2.1 CONCEPTUAL REVIEW

2.1.1 INTRODUCTION

Computed tomography (CT) is an essential medical imaging method that produces cross-sectional or volumetric images by utilizing computer-processed X-ray data obtained from multiple angles (Practice Parameter, 2016). Its importance in identifying and characterizing a diverse array of diseases has grown, especially with the development of multi-detector computed tomography (MDCT) scanners (Filippone et al., 2015).

Indications for an abdominal computed tomography scan encompass the assessment of urinary stones, renal masses, diffuse liver diseases, known or suspected pelvic masses and collections, evaluation of primary or metastatic cancers, post-operative investigations, congenital anomalies, and the assessment of bowel obstructions, perforations, appendicitis, and gastrointestinal bleeding. While there are no absolute contraindications for an abdominal computed tomography scan, relative contraindications include a history of contrast reactions, pregnancy or potential pregnancy, and unjustified requests from patients (Practice Parameter, 2016). Although MRI

provides superior visualization of soft tissue details, computed tomography scans can be performed on patients with metallic implants, those who are claustrophobic, and are generally more accessible and cost-effective (Hodler et al., 2018). In spite of the cost-effectiveness and availability of ultrasound, computed tomography scans offer a larger field of view that illustrates the relationships between organs and demonstrate a higher sensitivity in detecting nearly all stones and calcifications, as well as in staging tumors (Aklan & Mikhlafoy, 2018). Computed tomography is more readily accessible, less costly, provides faster examination times, offers higher spatial resolution and lesion detectability, and does not necessitate the intravenous injection of radiopharmaceuticals, unlike nuclear imaging (Hodler et al., 2018).

2.1.2 ANATOMY OF THE ABDOMEN AND PELVIS

The abdomen is the area situated between the thorax and pelvis, distinguished from the thorax by the diaphragm and open inferiorly to the pelvis through the pelvic inlet (Wright & Burns, 2022). It is surrounded by the anterolateral and posterior musculofascial walls, which are connected to the vertebral column, thoracic cage, and pelvic bones. These adaptable walls facilitate the movements of the abdominal organs. Clinically, the abdomen is categorized into Four quadrants; Right upper, right lower, left upper, and left lower quadrant. The abdomen is also divided into Nine regions (Right/left hypochondrium, lumbar, inguinal, epigastric, umbilical, and hypogastric). Abdominal organs are part of various systems e.g, Digestive (Stomach, intestines, liver, gallbladder, pancreas), Urinary (Kidneys, ureters and bladder), Immune (Spleen), Endocrine (Adrenal glands, pancreas).

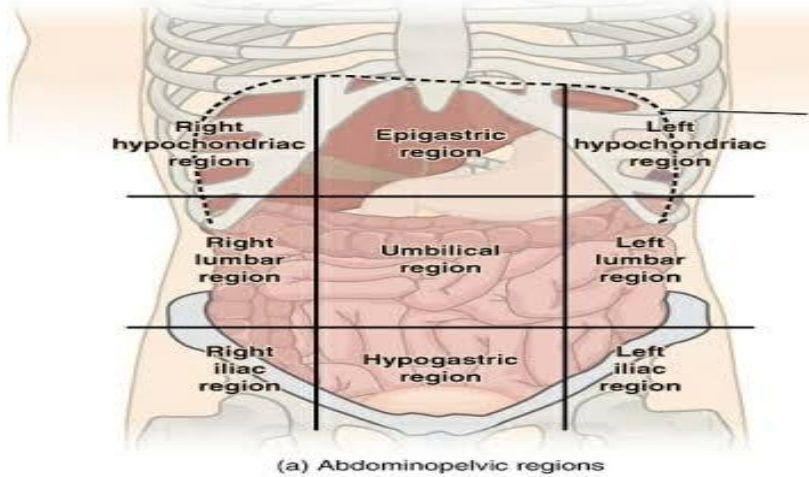


Figure 1: Abdominopelvic regions

The pelvis is a trunk region situated between the abdomen and the lower limbs, composed of the hip bones, sacrum, and coccyx (Chaudhry et al., 2023). It connects to the abdomen through the pelvic inlet and is enclosed below by the pelvic floor, which includes the levator ani and coccygeus muscles. The pelvis is categorized into; Greater pelvis (above the inlet), this area accommodates lower abdominal organs such as the terminal ileum, cecum, and sigmoid colon. Lesser pelvis (below the inlet), this section contains internal genital organs, distal urinary structures including the bladder and urethra, as well as the perineum.

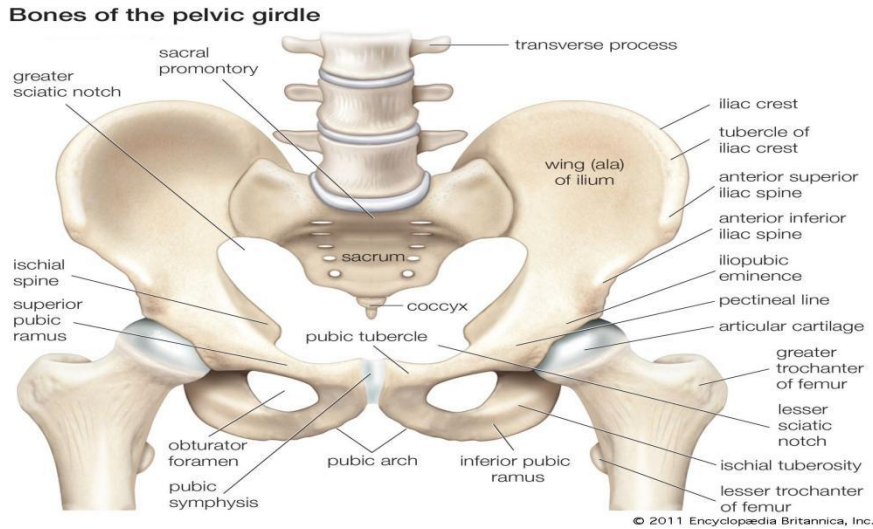


Figure 2: Bones of the pelvic regions

2.1.3 Concept of Abdomino-Pelvic Computed Tomography Imaging

Abdominal computed tomography scans are frequently recommended for evaluating conditions like urinary stones, kidney tumors, widespread liver disease, pelvic masses or fluid collections, primary or metastatic cancers, complications following surgery, congenital defects, bowel obstruction, perforation, appendicitis, and gastrointestinal hemorrhage. Although there are no definitive contraindications, relative contraindications encompass a history of allergic reactions to contrast agents, pregnancy or the possibility of pregnancy, and scan requests that lack justification (Practice Parameter, 2016).

Other imaging techniques utilized in abdominal imaging encompass Plain Film Radiography, Ultrasonography (US), Magnetic Resonance Imaging (MRI), and Nuclear Imaging. While Magnetic Resonance Imaging provides enhanced soft tissue contrast, computed tomography is often favored in various situations due to its compatibility with metallic implants, its

appropriateness for patients with claustrophobia, its greater availability, and its cost-effectiveness (Hodler et al., 2018). Although ultrasound is readily available and economical, computed tomography offers a wider field of view, superior anatomical detail, and increased sensitivity for detecting stones, calcifications, and for tumor staging (Aklan & Mikhlafy, 2018). In comparison to nuclear imaging, computed tomography is more readily accessible, quicker, less expensive, provides improved spatial resolution and lesion detectability, and does not necessitate intravenous radiopharmaceuticals (Hodler et al., 2018). In accordance with standard practice, healthcare institutions are required to document imaging finding patterns to aid clinical decision-making and policy formulation.

2.1.4 Abdominal And Pelvic Imaging Procedure

Computed tomography evaluation of the abdomen and pelvis demands more meticulous patient preparation compared to computed tomography imaging of other body regions. Typically, abdominal computed tomography requires the use of oral contrast agents to outline the intestinal lumen and distend the gastrointestinal tract. This is essential for distinguishing a fluid-filled bowel loop from a mass or abnormal fluid collection. Both dilute barium suspension and dilute water-soluble agents are effective options. Generally, the larger the volume of oral contrast given, the better the bowel visualization, with at least 600 ml preferred, though patient tolerance may limit intake.

To avoid misinterpretation, patients should consume only clear fluids for at least two hours before the scan, ensuring stomach contents are not mistaken for pathology. Air and water can also serve as effective low-attenuation contrast agents. For example, air or carbon dioxide is

often used to insufflate the colon in computed tomography colonography, creating strong negative contrast. Alternatively, water or low-Hounsfield unit (HU) barium suspensions (such as Volumen) may replace positive contrast media, as they preserve mucosal surface detail and do not obscure abdominal vessels in postprocessed images an important consideration in computed tomography angiography (CTA). Another advantage of low-HU contrast is that it does not conceal radiopaque stones in the urinary tract or common bile duct.

Rectal contrast is not commonly administered, except in cases such as colon cancer staging. On computed tomography, the bladder is best visualized when filled with urine or contrast. The vagina typically appears in cross-section as a soft tissue ellipse between the bladder and rectum; inserting a tampon can help delineate the vaginal canal by introducing air density.

Intravenous (IV) contrast agents enhance abdominal and pelvic computed tomography studies by highlighting blood vessels, increasing the density of vascular organs, and improving the distinction between lesions and normal tissues. Optimal use depends on correct timing, injection rate, and dosage. In most body scans, imaging must be completed before the intravenous contrast enters the equilibrium phase. With modern scanners, this is achievable, so pre-contrast scans are rarely performed in routine abdominal studies, except for specific purposes such as detecting fatty infiltration or other parenchymal changes.

For certain organs including the pancreas, liver, and kidneys or for abdominal computed tomography angiography (CTA), multiphasic imaging is commonly applied. When determining the best injection protocol, the same factors apply as in other regions of the body, the duration of contrast injection, the arrival time of contrast in the target vessels or organs, and the length of the scan.

Computed tomography scans of the abdomen and pelvis are commonly used to evaluate nearly all organs and major vessels. Radiologists typically review each structure systematically. Since each slice contains more detail than can be displayed with one window width and level, different settings are applied depending on the organ of interest.

A standard soft-tissue window setting (window width is 450, window level approximately 50) is suitable for most abdominal anatomy. For the liver, narrower “liver windows” (window width 150, window level 70) are preferred, as they enhance the detection of subtle lesions. The lung bases, which are often captured in upper abdominal slices, are best viewed using lung windows (window width 1500, window level approximately 600). Bone windows (window width 2000, window level 600) are useful for detecting skeletal abnormalities.

The display field of view (DFOV) should cover only the necessary anatomy, usually limited to the skin margins of the key regions. Portions of the arms raised above the head are often excluded to prevent an unnecessarily wide display of field of view. For consistency, it is recommended to use the same display of field of view as in prior studies, unless changes in the patient’s condition such as significant weight gain or loss require adjustment (e.g., large weight gain). Maintaining the same display of field of view as in prior studies allows for straightforward side-by-side comparison of structural or lesion size changes on picture archiving and communication system monitors or film viewboxes.

Although scout images provide useful landmarks to guide where cross-sectional imaging should begin and end, technologists must ensure that all the relevant anatomy is included in the scan. For example, abdominal imaging usually starts at the lung bases and ends at the iliac crests. However, if slices at the iliac crest still show portions of the liver, the scan should be extended

until the liver is fully captured. Likewise, scanning should not begin or terminate through a visible abnormality, complete coverage of the area of interest is essential.

In most abdominal and pelvic computed tomography protocols, the patient is positioned supine on the scanner table with the arms raised above the head. In certain cases, however, altering the patient's position and acquiring additional slices can provide useful diagnostic information. For example, when initial images do not clearly separate the pancreas from the duodenum, the patient may be given extra oral contrast and rescanned in the right lateral decubitus position to improve visualization.

During computed tomography acquisition, patients are instructed to hold their breath to minimize motion and reduce image artifacts. Movement during scanning can cause displacement, distortion, or blurring of anatomic structures. Although modern multi detector computed tomography scanners have decreased the impact of motion, artifacts from cardiac activity, vascular pulsations, and bowel peristalsis can still occur.

The number of abdominal and pelvic computed tomography protocols varies widely between institutions, ranging from only a few (e.g., two) to more than forty. Some protocols are broad, such as routine abdomen and pelvis studies, while others are tailored to address specific clinical questions or target individual organs (e.g., suspected appendicitis, renal mass evaluation).

In certain centers, radiologists review scans while the patient is still on the table, allowing immediate adjustments if needed. In others, images are not checked until after the patient has left, which increases throughput but may require recall if scans are inadequate or ambiguous. A hybrid approach is also used at some facilities, where only select studies such as adrenal

protocols are reviewed immediately, since these may require on-the-spot modifications or even intervention. In such institutions, technologists are typically encouraged to review images carefully and consult a radiologist whenever they suspect abnormal findings ((Romans, 2011, p. 300).

2.1.5 Indications for Abdomino-Pelvic Computed Tomography Scans

Abdomino-pelvic computed tomography scans are commonly used for;

1. Evaluation of non-specific abdominal pain.
2. Detection and staging of intra-abdominal or pelvic malignancies.
3. Assessment of trauma or suspected internal bleeding.
4. Diagnosis of inflammatory and infectious conditions (e.g., appendicitis, diverticulitis, pelvic inflammatory disease).
5. Investigation of urological or gynecological symptoms Preoperative planning and post-operative follow-up.

2.1.6 Common Pathologies Detected on Abdomino-Pelvic Computed Tomography

Abdomino-pelvic computed tomography can reveal a wide range of conditions such as:

1. Neoplastic conditions (e.g., hepatocellular carcinoma, ovarian tumors, prostate cancer).
2. Inflammatory diseases (e.g., colitis, pancreatitis).
3. Infectious diseases (e.g., abdominal tuberculosis, abscesses).

4. Trauma-related injuries (e.g., organ lacerations, hemorrhage).
5. Congenital anomalies or vascular malformations.

The pattern and prevalence of these findings often reflect the health burden and lifestyle of the population under study. For example, hepatic and renal diseases are relatively prevalent in Nigeria due to factors like hepatitis infection, hypertension, and poor access to early healthcare.

2.1.7 Importance of Understanding the common findings in Computed Tomography examination.

Understanding the distribution and frequency of abdomino-pelvic computed tomography findings helps in:

1. Epidemiological surveillance and early disease detection.
2. Enhancing diagnostic confidence among clinicians and radiologists.
3. Developing region-specific diagnostic and referral protocols.
4. Improving resource allocation and planning in health institutions.

2.1.8 Regional and Demographic Considerations

The pattern of abdomino-pelvic computed tomography findings may vary based on factors such as age, gender, socioeconomic status, and geography. For instance, men may present more with urological or prostate conditions, while women may show more gynecologic-related findings. Moreover, urban populations may have higher incidences of malignancies due to environmental exposures and lifestyle changes.

Documenting the common findings in computed tomography examinations supports evidence-based clinical decision-making. It also aids radiology departments in protocol standardization and optimization of radiation doses for common clinical indications. From a policy perspective, it guides investment in imaging equipment, training, and public health initiatives targeting the most common pathologies in the region.

2.2 EMPERICAL REVIEW

Several studies have compared findings observed among Nigerian adult of both genders in abdomino-pelvic computed tomography imaging.

Adama et al. (2024) conducted a retrospective study spanning 2 years and 3 months, reviewing 53 patients who underwent surgery for abdominal masses at the General Surgery department of HGR. Abdominal masses accounted for 6.7% of surgical cases, with an average patient age of 41.3 years and a significant female predominance of 75.5%. In most instances, the masses were palpable, and all patients received abdominal-pelvic ultrasound, which successfully identified the mass origin in 75.5% of cases. Computed tomography scans were utilized in 52.8% of the cases, confirming diagnoses in 89.3% of those patients. Uterine fibroids emerged as the most prevalent cause, representing 35.8%. In cases where imaging results were inconclusive, exploratory laparotomy was deemed necessary. Surgery was the primary mode of treatment, with laparoscopy employed in 22.6% of cases. Postoperative complications were observed in 7.5% of patients, and the mortality rate stood at 5.6%, primarily associated with malignancy and the size of the mass. This study underscores the critical role of imaging in diagnosis and highlights surgery as the definitive treatment.

Hassan et al. (2021) conducted a retrospective study at the Radiology Department of Aminu Kano Teaching Hospital in Nigeria, covering the period from March 2020 to September 2020. This analysis involved 664 abdominal Computed tomography scan records of adult patients, comprising 338 males and 326 females, with a mean age of approximately 50.45 years. Jaundice was identified as the most prevalent clinical indication, occurring in 12.9% of males and 9.5% of females, followed by abdominal swelling and abdominal mass. Less common indications included primary liver cell carcinoma, ascites, and pseudopancreatic cysts. The most frequently detected abnormalities were pancreatic lesions, followed by hepatobiliary lesions. The findings of this study highlight the necessity for focused investigations into the causes of pancreatic tumors and suggest that these results could inform clinical practice and healthcare planning.

Triantopoulou et al. (2013) conducted a study and examined 18 instances of pathologically confirmed abdominopelvic actinomycosis (15 females, 3 males; average age 50 years). All subjects underwent contrast-enhanced computed tomography imaging. Eleven individuals had a history of using an intrauterine contraceptive device (IUCD). The sigmoid colon was the most frequently affected area. Computed tomography results generally revealed concentric, uniformly enhancing thickening of the bowel wall and widespread infiltration of pericolonic fat. Pelvic abscesses were identified in 11 individuals, while pelvic or peritoneal masses were observed in 3 cases. Abdominal wall infiltration was noted in 3 patients, and thoracic dissemination was detected in 1. The study concludes that actinomycosis should be included in the differential diagnosis when imaging displays these distinctive patterns, even in patients who have not used an IUCD.

Yunusa et al. (2013) conducted a retrospective analysis at the Radiology Department of Usmanu Danfodiyo University Teaching Hospital in Sokoto, examining abdominal helical computed tomography scans sourced from various clinical departments and adjacent tertiary centers. A total of thirty-five patients (18 males and 17 females), ranging in age from 1 to 78 years (with a mean age of 46.6 years), were included in the study. The predominant age group for computed tomography referrals was 46–60 years, accounting for 34.3%. The primary reason for the scans was the suspicion of an abdominal mass (28.6%), followed by the assessment of known renal masses (20%). The most commonly observed computed tomography findings included pancreatic masses (20.3%), appendiceal masses (8.7%), and bladder masses (8.6%). The study concludes that abdominal masses are the leading cause for abdominal computed tomography scans, with pancreatic masses being the most frequently identified finding.

Chukwu et al. (2021) carried out a hospital-based descriptive study at the University of Nigeria Teaching Hospital (UNTH), Enugu, evaluating 210 adult abdomino-pelvic computed tomography scans over a 15-month period. The research revealed that 61% of the patients were males, and the most frequently affected age group was 41–50 years. Abdominal pain (29.5%) and suspicion of malignancy (21.0%) were the leading reasons for computed tomography referral. Liver-related abnormalities, including hepatomegaly and cirrhosis, accounted for 30% of total findings, while renal cysts and ascites were identified in 11.4% and 9.5% of patients respectively. The study emphasized that liver and renal disorders constitute a significant portion of computed tomography detected pathologies in Nigerian adults, and recommended enhanced screening for hepatic diseases in high-risk populations.

Olayinka et al. (2022) conducted a retrospective analysis of 312 abdomino-pelvic computed tomography examinations at the Radiology Department of Lagos University Teaching Hospital, Nigeria. The study assessed patient demographics, clinical indications, and radiological findings over a 12-month period. The majority of the patients were within the 40–60-year age group (48.1%), with males comprising 56% of the study population. The most common indications for computed tomography were abdominal pain (27.6%), suspected malignancy (18.9%), and trauma (10.3%). The predominant computed tomography findings were hepatic lesions (23.4%), renal pathologies (16.2%), and pelvic masses (9.8%). The study concluded that computed tomography remains an indispensable diagnostic tool for evaluating complex abdominal and pelvic pathologies, particularly in cases where ultrasound is inconclusive.

CHAPTER THREE

RESEARCH METHODOLOGY

3.1 Introduction

This study was conducted to evaluate the common findings in abdomino-pelvic computed tomography (CT) examinations among adult patients at the University of Benin Teaching Hospital (UBTH), Benin City, Edo State, Nigeria.

3.2 Research Setting

The study was carried out at the Department of Radiology, University of Benin Teaching Hospital (UBTH), located at P.M.B. 1111, Benin City, Edo State, Nigeria. UBTH is a major tertiary healthcare institution that serves as a referral center for Edo State and neighboring regions, providing advanced diagnostic and imaging services including computed tomography.

3.3 Study Design

The research adopted a retrospective design. Abdomino-pelvic imaging reports available at the Radiology Department of UBTH from May 2024 to May 2025 were reviewed and analyzed.

3.4 Target Population

The target population comprised adult patients aged 18 years and above who underwent abdomino-pelvic computed tomography (CT) examinations at the Radiology Department of UBTH within the study period.

Inclusion Criteria

- Adult patients above the age of 18 who was referred for abdominopelvic CT examination from January 2024 - June 2025.
- Abdominopelvic CT scan for various indications.
- Complete CT data information available.
- Focused on Nigerian Population

Exclusion Criteria

- Non-adult patients and pregnant women.
- Non-abdominopelvic CT scan.
- Incomplete CT data information. To
- Non-Nigerian Population.

3.5 Sampling Technique and Sample Size

A purposive sampling technique was employed to select the records of adult patients who had undergone abdomino-pelvic imaging between May 2024 and May 2025. The sample consisted of all eligible patient records within the specified period that contained complete and readable computed tomography reports and relevant clinical information.

Sample Size:

The total number of patients included in the study was determined from the hospital's radiology records and departmental logs. In total, 105 adult patient records that met the inclusion criteria were analyzed.

3.6 Instrument for Data Collection

A structured data extraction sheet was used to ensure consistency in data collection. Data were extracted from patient records and computed tomography reports by trained research assistants under supervision. The data extraction sheet included variables such as:

Demographic data: age, sex, and hospital identification number.

Clinical data: presenting symptoms and clinical indications for computed tomography examination.

Radiological data: major computed tomography findings in the abdomen and pelvis.

All extracted data were handled confidentially, and patient identifiers were removed to ensure privacy.

3.7 Validity of Instrument

The data extraction sheet was reviewed by the project supervisor and a senior radiographer at UBTH to ensure that it captured all relevant variables accurately and conformed to clinical reporting standards. Their expert input helped to enhance the content and construct validity of the instrument.

3.8 Reliability of Instrument

Reliability was ensured through standardized data collection procedures. Trained research assistants used the same data extraction sheet to collect information from all records consistently. A pilot review of a few records was first conducted to confirm uniformity in data recording before the full extraction commenced.

3.9 Method of Data Collection

Data were collected retrospectively from the archived patient files and radiologist reports at the Radiology Department of UBTH. Only cases that met the inclusion criteria; adult patients who underwent abdomino-pelvic computed tomography between May 2024 and May 2025 were selected. Incomplete or illegible records were excluded. Extracted data were cross-checked to ensure accuracy before analysis.

3.10 Method of Data Analysis

The data were analyzed using the Statistical Package for the Social Sciences (SPSS) version 27. Descriptive statistics such as frequencies and percentages were used to summarize demographic characteristics, clinical indications, and computed tomography findings. Inferential statistics were employed to determine the associations between demographic variables and computed tomography findings. A p-value of less than 0.05 was considered statistically significant.

3.11 Ethical Consideration

Ethical approval for the study was obtained from the Health Research Ethics Committee of the University of Benin Teaching Hospital (UBTH). Owing to the retrospective nature of the study, informed consent from patients was not required. All patient information was anonymized, and confidentiality was strictly maintained throughout the research process.

CHAPTER FOUR

DATA PRESENTATION AND ANALYSIS

4.1 Introduction

This chapter presents the data collected for the study titled “Common Findings in Abdomino-Pelvic Computed Tomography Examinations in Nigerian Adults (A Case Study of the University of Benin Teaching Hospital)”. The data were analyzed using descriptive statistics such as frequencies and percentages and are presented in tables for clarity. The total number of patient records analyzed was 105, derived from the Radiology Department of the University of Benin Teaching Hospital.

4.2 Socio-Demographic Characteristics of Patients

Table 4.1: Distribution of Patients by Sex

Sex	Frequency	Percentage (%)
Male	58	55.2
Female	47	44.8
Total	105	100

Table 4.2: Distribution of Patients by Age Group

Age Group (Years)	Frequency	Percentage (%)
0–18	1	1.0
19–40	22	21.0
41–60	50	47.6
61–80	29	27.6
81+	3	2.9
Total	105	100

The results indicate that most patients (47.6%) were between 41–60 years of age, followed by 27.6% within 61–80 years. Males constituted a slightly higher proportion (55.2%) compared to females (44.8%).

The socio-demographic profile of the sample provides important context for the radiological patterns observed in this study. A total of 105 patients were analysed. Males constituted 55.2% (n = 58) of the sample while females constituted 44.8% (n = 47), indicating a slight male predominance. The age distribution showed that nearly half of the patients (47.6%, n = 50) were within the 41–60 years age group, 27.6% (n = 29) were 61–80 years, 21.0% (n = 22) were 19–40 years, with only 1.0% (n = 1) below 18 years and 2.9% (n = 3) aged 81 years and above.

The observed male predominance (55.2%) may reflect sex differences in disease incidence and health-seeking behaviours that are relevant to abdomino-pelvic pathology. In many hospital-based imaging series in Nigeria and similar settings, a modest male excess is common and has been attributed to higher rates of certain urological conditions, occupational exposures, trauma, and a greater tendency for males to present with advanced disease requiring imaging (see Chukwu et al., 2021; Olayinka et al., 2022). It is also possible that referral patterns within the hospital — for example more frequent surgical or urology referrals for men — contributed to this imbalance. The male predominance should therefore be interpreted in light of local referral practices and case mix rather than as a universal epidemiologic fact.

The age distribution, skewed towards middle-aged and older adults, is consistent with the nature of many abdomino-pelvic conditions that require computed tomography for diagnosis or staging. With 71% of the sample aged above 40 years, the dataset largely represents an adult population in which degenerative, neoplastic and chronic liver or renal conditions are more likely. This pattern parallels findings from other Nigerian tertiary centres where computed tomography referrals peak in the 4th–6th decades of life (Hassan et al., 2021; Chukwu et al., 2021; Olayinka et al., 2022). The predominance of the 41–60 year group suggests that the burden of clinically

important hepatic, renal and neoplastic disease in this setting is concentrated in middle age — a fact that has implications for screening, early detection and health resource planning.

From a clinical-epidemiological perspective, the combination of a mostly middle-aged/older sample and slight male excess helps explain why liver-related findings, neoplastic lesions, and complications such as ascites/pleural effusion were common in the radiologic results (see Section 4.4). Many primary liver diseases (including chronic hepatitis, cirrhosis and hepatocellular carcinoma) and metastatic conditions typically affect adults in this age bracket; similarly, age is a risk factor for renal cysts and other degenerative lesions that appear on computed tomography.

It is useful to consider potential biases and limitations associated with these demographic results. First, the study is hospital-based and retrospective, thus subject to referral and selection bias: patients who undergo computed tomography are not a random sample of the population but often those with more severe, complicated or unexplained symptoms. Younger patients with mild disease may be under-represented if they are managed with ultrasound or clinical follow-up instead of computed tomography. Second, the time window and sampling approach (purposive selection of complete records between May 2024 and May 2025) may influence the observed distribution; seasonal variations or temporary service changes could affect which age groups presented during the period. Finally, sociodemographic data in records are occasionally incomplete — while not detected in the final cleaned sample used here, missing or miscoded ages/sex entries in the original logs can bias frequency estimates if not handled systematically.

4.3 Clinical Indications for Abdomino-Pelvic CT Scans

Table 4.3: Frequency and Percentage Distribution of Clinical Indications

Clinical Indication	Frequency	Percentage (%)
Abdominal pain/swelling/distension	18	17.1
Suspected or rule-out cancer (various types)	17	16.2
Jaundice	7	6.7
Trauma (blunt, penetrating, RTA)	7	6.7
Known cancer (follow-up/staging)	6	5.7
Suspected liver disease (PLCC, cirrhosis, HBV, etc.)	6	5.7
Other causes (renal stones, hernia, weight loss, etc.)	44	41.9
Total	105	100

The most common reason for referral was abdominal pain or distension (17.1%), followed closely by suspected malignancy (16.2%). A considerable portion (41.9%) of scans were conducted for other causes including renal stones, hernias, and weight loss.

The clinical indications for abdomino-pelvic computed tomography (CT) scans in this study provide valuable insight into the major reasons patients are referred for advanced imaging in this setting. As shown in Table 4.3, the most common indication was abdominal pain, swelling, or distension, accounting for 17.1% of all cases. This was followed closely by suspected or rule-out malignancy (16.2%), jaundice (6.7%), and trauma (6.7%). Other indications included known cancer (follow-up/staging) and suspected liver disease (each 5.7%), while a large proportion (41.9%) fell under miscellaneous causes, such as renal stones, hernias, and unexplained weight loss.

The predominance of abdominal pain and distension as an indication aligns with the general clinical pattern reported in previous Nigerian and international studies. According to Olayinka et al. (2022), abdominal pain was the leading reason for computed tomography referral in their Lagos cohort, representing 27.6% of all cases. Similarly, Chukwu et al. (2021) and Adama et al. (2024) observed that non-specific abdominal complaints were among the most frequent presentations for computed tomography scanning in tertiary hospitals. This finding reflects the non-specific nature of abdominal pain, which may result from a wide range of conditions — hepatobiliary diseases, intestinal obstruction, intra-abdominal masses, or inflammatory processes — many of which require computed tomography for definitive evaluation.

The high frequency of cancer-related referrals (both suspected and follow-up/staging) underscores the growing reliance on computed tomography in oncologic diagnosis and management. Together, suspected and known cancers accounted for 21.9% of all computed tomography requests in this study. This is comparable to the 18.9% reported by Olayinka et al. (2022) in Lagos and the 21.0% documented by Chukwu et al. (2021) in Enugu. The pattern suggests an increasing awareness among clinicians of the diagnostic value of computed tomography for tumour detection, staging, and metastasis assessment. The use of computed tomography in follow-up cases also demonstrates its critical role in treatment monitoring, particularly in patients undergoing chemotherapy, radiotherapy, or surgical intervention.

The 6.7% incidence of trauma-related indications (including blunt and penetrating injuries and road traffic accidents) is consistent with findings by Hassan et al. (2021), who reported 7.2% in their study at Aminu Kano Teaching Hospital. The presence of trauma cases highlights the utility of abdomino-pelvic computed tomography in emergency medicine, where rapid evaluation of internal bleeding, organ laceration, and other injuries is essential. The value of computed tomography in trauma evaluation has been well-established globally, with studies such as Triantopoulou et al. (2013) emphasizing its role in guiding surgical decision-making and reducing diagnostic uncertainty.

A smaller proportion of the computed tomography requests (5.7%) were due to suspected liver disease, such as primary liver cell carcinoma (PLCC), cirrhosis, and hepatitis B virus (HBV)-related complications. This aligns with the high burden of hepatic disease in Nigeria, particularly due to the endemicity of chronic HBV infection. The close overlap between these clinical indications and the actual findings reported in Section 4.4 (where liver pathologies were

predominant) further validates the accuracy of clinical judgment in computed tomography referrals within this population.

The large “other” category (41.9%) indicates the wide range of non-specific and less common reasons clinicians request computed tomography imaging. These include renal colic, suspected hernias, unexplained weight loss, ascites of uncertain origin, and pelvic masses. This broad range of indications reflects both the diagnostic versatility of computed tomography and the limitations of other imaging modalities (such as ultrasound) in resolving complex or ambiguous abdomino-pelvic cases. In many tertiary hospitals in Nigeria, computed tomography is the next-line investigation when ultrasonography is inconclusive or when malignancy must be ruled out.

Overall, the clinical indication profile observed here mirrors the disease burden in Nigerian adults, characterized by high rates of abdominal pain syndromes, hepatobiliary disorders, and malignancies. It also demonstrates the central role of computed tomography scanning in both emergency and elective diagnostic pathways. The data suggest that clinicians in this environment have adopted computed tomography as a standard tool for early diagnosis, staging, and follow-up of complex abdominal conditions, consistent with international best practice.

4.4 Radiological Findings

Table 4.4: Frequency and Percentage Distribution of Major computed tomography Findings

Radiological Finding	Frequency	Percentage (%)
Liver-Related Findings		
Hepatomegaly	24	22.9

Liver cirrhosis	8	7.6
Primary liver cell carcinoma (PLCC)	8	7.6
Hepatic/Liver cyst(s)	7	6.7
Liver metastasis	6	5.7

Fluid Collections

Ascites	11	10.5
Pleural effusion (uni/bilateral)	11	10.5

Other Common Findings

Various cancers (gastric, renal, colorectal, etc.)	20	19.0
Renal cyst(s)	9	8.6
Cholelithiasis (gallstones)	6	5.7
Splenomegaly	5	4.8
Hernia (various types)	5	4.8
Normal findings	4	3.8
Total	105	100

Liver-related abnormalities were predominant, with hepatomegaly being the most common (22.9%), followed by liver cirrhosis and primary liver cell carcinoma (7.6% each). Ascites and

pleural effusion were also notable findings (10.5% each). A wide range of cancers and other pathologies were identified, while 3.8% of the scans showed normal findings.

The radiological findings from the 105 abdomino-pelvic computed tomography examinations revealed a broad spectrum of pathologies, reflecting the diversity of clinical presentations in the study population. The most frequent abnormalities were liver-related, followed by fluid collections and various cancers affecting other abdominal and pelvic organs.

Among the hepatic findings, hepatomegaly was the single most common abnormality, observed in 22.9% of cases. This was followed by liver cirrhosis (7.6%), primary liver cell carcinoma (PLCC) (7.6%), hepatic cysts (6.7%), and liver metastases (5.7%). The high occurrence of hepatic abnormalities aligns with the well-documented burden of liver diseases in Nigeria, largely driven by hepatitis B and C infections, alcohol use, and aflatoxin exposure. These results are consistent with findings by Chukwu et al. (2021) and Olayinka et al. (2022), who both reported liver-related pathologies as the predominant computed tomography findings in adult patients. This underscores the significant diagnostic role of computed tomography in the evaluation of hepatic morphology, tumour detection, and complication assessment.

Fluid collections, comprising ascites (10.5%) and pleural effusion (10.5%), were also prominent in this study. These findings often occur as secondary manifestations of advanced hepatic disease, malignancy, or chronic infections. The co-occurrence of ascites and pleural effusion in several patients further supports the likelihood of underlying liver or malignant pathologies. This trend corresponds with the observations of Adama et al. (2024) and Hassan et al. (2021), who emphasized that such fluid accumulations frequently accompany late-stage disease presentations in Nigerian hospitals.

The category of other common findings included various cancers (19.0%), renal cysts (8.6%), cholelithiasis (5.7%), splenomegaly (4.8%), and hernias (4.8%). The diversity of these lesions highlights computed tomography's effectiveness in detecting multi-organ pathologies, particularly in patients with complex abdominal symptoms. The 19% prevalence of cancers — both primary and metastatic — further supports the increasing trend of oncologic imaging demand, reflecting the role of computed tomography in tumour detection, staging, and treatment planning. Studies by Triantopoulou et al. (2013) and Yunusa et al. (2013) similarly noted that computed tomography remains indispensable in assessing both solid-organ and soft-tissue malignancies of the abdomen and pelvis.

Interestingly, 3.8% of the scans were reported as normal. Although this represents a small proportion, it suggests that computed tomography is sometimes used for patients with non-specific or functional abdominal complaints where organic pathology is not evident. This figure compares closely with that of Hassan et al. (2021), who reported 4.5% normal findings in their study, indicating that despite careful clinical selection, a small fraction of computed tomography scans may yield negative results — a reflection of computed tomography's role as both a confirmatory and exclusionary diagnostic tool.

Overall, the findings demonstrate that liver-related pathologies remain the leading causes of abnormal abdomino-pelvic computed tomography results in adults, followed by neoplastic lesions and fluid collections. This pattern reinforces the relationship between age, clinical presentation, and disease burden, as discussed in Sections 4.2 and 4.3. The results further confirm the critical importance of computed tomography imaging in the diagnosis, characterization, and follow-up of abdominal diseases in tertiary healthcare settings.

4.5 Summary of Quantitative Results

The quantitative results of this study summarize key demographic, clinical, and radiological patterns observed among the 105 patients who underwent abdomino-pelvic computed tomography examinations. The findings reveal that most patients were middle-aged or elderly, with a slight male predominance (55.2%). The 41–60 years age group formed the largest proportion of the study population (47.6%), followed by those aged 61–80 years (27.6%). This pattern is consistent with similar Nigerian studies (Hassan et al., 2021; Olayinka et al., 2022), which reported increased computed tomography utilization among adults, largely due to the higher prevalence of age-related and chronic abdominal diseases.

Clinically, abdominal pain and distension (17.1%) were the most common reasons for referral, followed by suspected malignancy (16.2%) and trauma (6.7%). This reflects the wide diagnostic utility of computed tomography in evaluating non-specific abdominal symptoms and ruling out malignancy. The relatively high proportion of cancer-related referrals also demonstrates the growing reliance on computed tomography in oncologic evaluation, staging, and follow-up (Chukwu et al., 2021; Olayinka et al., 2022).

Radiologically, liver-related abnormalities were the most frequent findings, with hepatomegaly (22.9%) being the single most common, followed by liver cirrhosis and primary liver cell carcinoma (7.6% each). Other frequent findings included ascites and pleural effusion (10.5% each), as well as various cancers (19%) affecting multiple organs. Only 3.8% of the scans were reported as normal, indicating a high diagnostic yield of computed tomography in this clinical context.

Overall, the quantitative data indicate that abdomino-pelvic computed tomography scans are most commonly performed in middle-aged and elderly patients, primarily for the evaluation of abdominal pain, suspected hepatic disease, and malignancies. The predominance of liver-related and neoplastic pathologies underscores the high burden of hepatobiliary and oncologic conditions in the study environment and the critical diagnostic role of computed tomography imaging in their detection and management.

CHAPTER FIVE

DISCUSSION, SUMMARY OF DISCUSSION, CONCLUSION AND RECOMMENDATIONS

5.1 DISCUSSION

This study investigated the common findings in abdomino-pelvic computed tomography (CT) examinations among adult patients at the University of Benin Teaching Hospital. The discussion integrates the demographic characteristics, clinical indications, and radiological findings to give a comprehensive picture of the disease patterns observed and their clinical implications.

The study revealed that males (55.2%) slightly outnumbered females (44.8%), which aligns with studies by Chukwu et al. (2021) and Olayinka et al. (2022), who also reported male predominance in abdomino-pelvic computed tomography utilization in Nigerian tertiary hospitals. This gender distribution may be related to the higher incidence of hepatic and urological diseases among males, as well as their greater exposure to occupational hazards and

trauma. Cultural and socioeconomic factors influencing healthcare access may also play a role, as males tend to seek hospital-based investigations more readily than females in many parts of Nigeria.

Age distribution showed that the majority of patients (71%) were above 40 years, with those aged 41–60 years forming the largest group (47.6%). This indicates that abdomino-pelvic pathologies are more common among middle-aged and elderly adults, corroborating earlier findings by Hassan et al. (2021) and Yunusa et al. (2013). The concentration of older adults suggests that degenerative and neoplastic diseases become more prevalent with age, often requiring advanced imaging for diagnosis. The reduced frequency of younger patients (below 40 years) further supports the notion that most abdomino-pelvic computed tomography examinations are conducted for chronic, age-related, or malignancy-associated conditions rather than acute or congenital disorders.

Analysis of clinical indications showed that abdominal pain, swelling, or distension (17.1%) were the leading reasons for referral, followed by suspected malignancy (16.2%), trauma (6.7%), and suspected liver disease (5.7%). This finding mirrors earlier research by Adama et al. (2024) and Olayinka et al. (2022), who also identified abdominal pain and suspicion of cancer as the most common computed tomography indications. These results demonstrate the increasing clinical reliance on computed tomography as a definitive diagnostic tool for complex or unresolved abdominal symptoms. The significant number of cancer-related referrals also highlights computed tomography's essential role in oncologic staging, metastasis assessment, and post-treatment follow-up.

Trauma-related cases constituted 6.7% of the indications, consistent with the 7.2% reported by Hassan et al. (2021). This underscores computed tomography's indispensable role in emergency

trauma evaluation, particularly for detecting internal organ injuries that may not be apparent on ultrasound or physical examination. The wide range of 'other' indications (41.9%)—including renal stones, hernias, and weight loss—demonstrates the broad applicability of computed tomography across multiple abdominal conditions, reaffirming its versatility in diagnostic radiology.

Radiologically, the study identified liver-related abnormalities as the most prevalent computed tomography findings, with hepatomegaly (22.9%), liver cirrhosis (7.6%), and primary liver cell carcinoma (7.6%) being the dominant lesions. These findings are consistent with reports from Olayinka et al. (2022) and Chukwu et al. (2021), who observed similar hepatic dominance in their cohorts. The high prevalence of liver diseases in this study reflects Nigeria's substantial burden of chronic hepatitis B and C infections, alcohol-related liver injury, and exposure to hepatotoxins such as aflatoxin. The co-existence of ascites (10.5%) and pleural effusion (10.5%) further supports the presence of advanced hepatic or metastatic disease in several patients.

Other notable computed tomography findings included various cancers (19%), renal cysts (8.6%), cholelithiasis (5.7%), and splenomegaly (4.8%). These results emphasize computed tomography's value in detecting multi-system pathologies, especially when multiple organs are affected simultaneously. The low number of normal findings (3.8%) indicates that clinicians are using computed tomography judiciously and that the modality has a high diagnostic yield when appropriately indicated.

Overall, the study findings agree strongly with earlier research across Nigeria and other developing countries. The consistency of results reported by Adama et al. (2024), Olayinka et al. (2022), Chukwu et al. (2021), and Yunusa et al. (2013) confirms that hepatic and oncologic diseases dominate the spectrum of abdomino-pelvic computed tomography findings in adults.

This pattern underscores the rising importance of computed tomography in detecting diseases at stages where clinical assessment alone may be insufficient.

OBJECTIVES AND RESULT LINKING

Objective 1: To ascertain the frequency and distribution of abdominopelvic Computed Tomography findings among adult patients at UBTH.

Result: Findings of the study showed that the frequency and distribution of abdominopelvic Computed Tomography findings among adult patients at UBTH was more of liver related conditions with hepatomegaly having the highest frequency of 24 and a percentage of 22.9%.

Objective 2: To recognize the common pathological conditions identified through abdominopelvic Computed Tomography scans along with their demographic variations including age, sex and clinical presentation.

Result: Findings showed that the most common pathological conditions identified through abdominopelvic Computed Tomography scans were abdominal pain, swelling or distention which were a leading cause of referral followed by suspected malignancy, trauma and suspected liver disease. Findings also showed that gender distribution may be related to higher incidence of hepatic and urologic conditions which is frequent in males as a result of greater exposure to occupational hazard and trauma. The study also showed that abdominopelvic pathologies are more common among middle aged adults.

5.2 SUMMARY OF DISCUSSION

The results of this study clearly demonstrate that abdomino-pelvic computed tomography (CT) examinations provide vital diagnostic insights into a wide range of diseases affecting adults, particularly those involving the liver and other abdominal organs. The analysis revealed that the majority of patients who underwent abdomino-pelvic computed tomography were middle-aged and elderly adults, indicating that the burden of abdominal and pelvic pathologies increases with advancing age. This finding aligns with the understanding that degenerative, neoplastic, and chronic hepatic conditions are more prevalent among older populations, thereby necessitating more frequent utilization of advanced imaging modalities such as computed tomography for accurate diagnosis and management.

A slight male predominance was observed among the patients, which may reflect differences in disease incidence, occupational exposure, and healthcare-seeking behavior between men and women. Males are more likely to present with hepatic, urological, and trauma-related conditions, all of which frequently require computed tomography evaluation.

The most common clinical indications for abdomino-pelvic computed tomography were abdominal pain, suspected malignancy, and trauma. This trend underscores the central role of computed tomography in evaluating non-specific abdominal symptoms, investigating possible neoplastic diseases, and assessing internal injuries following traumatic events. It also highlights clinicians' growing reliance on computed tomography imaging as a confirmatory diagnostic tool in complex or ambiguous clinical cases where other modalities, such as ultrasound or plain radiography, may not provide adequate information.

Liver-related pathologies constituted the most frequent computed tomography findings in this study, with hepatomegaly, liver cirrhosis, and primary liver cell carcinoma being the leading abnormalities. This dominance of hepatic diseases reflects the persistent burden of liver disorders in Nigeria, which can be attributed to factors such as chronic viral hepatitis, alcohol use, and exposure to hepatotoxic substances. In addition to these, ascites and pleural effusion were commonly encountered as secondary findings, often indicating advanced stages of hepatic or malignant diseases.

The relatively low rate of normal findings (3.8%) indicates that computed tomography requests were generally well justified and clinically appropriate. This suggests that referring physicians made rational use of the modality, and that computed tomography scanning maintained a high diagnostic yield within the study population.

Overall, the findings of this study correspond closely with those of previous research conducted in other Nigerian tertiary hospitals, such as the works of Chukwu et al. (2021), Olayinka et al. (2022), and Hassan et al. (2021), all of which reported similar patterns of demographic distribution, clinical indications, and predominant hepatic abnormalities. This consistency across studies supports the reliability of the current findings and strengthens the evidence that abdomino-pelvic computed tomography scanning remains an indispensable diagnostic tool for identifying and managing a broad spectrum of abdominal and pelvic diseases among adult patients in Nigeria.

5.3 CONCLUSION

This study concludes that abdomino-pelvic computed tomography (CT) is an indispensable diagnostic modality in the evaluation of abdominal and pelvic diseases among adult patients. Its

high diagnostic yield and ability to produce detailed cross-sectional images make it a vital tool for clinicians and radiologists in identifying, characterizing, and managing a wide spectrum of pathological conditions. The findings of this study revealed that the liver and adjacent structures were the most frequently affected organs, indicating a high burden of hepatobiliary diseases within the study population. Common hepatic abnormalities such as hepatomegaly, liver cirrhosis, and primary liver cell carcinoma were recurrent, reflecting the significant prevalence of chronic liver diseases and malignancies in the Nigerian adult population.

Furthermore, the study demonstrated that the major clinical indications for abdomino-pelvic computed tomography referrals were abdominal pain, suspected malignancy, and trauma. This trend underscores the crucial role of computed tomography in providing diagnostic clarity in cases where other imaging modalities, such as ultrasound or plain radiography, may be inconclusive. The high proportion of malignancy-related referrals also highlights the growing dependence on computed tomography imaging for tumor detection, staging, and follow-up in oncologic practice.

In addition, the presence of fluid collections such as ascites and pleural effusion, as well as various neoplastic and cystic lesions, reinforces computed tomography's versatility in assessing both primary and secondary disease manifestations. The relatively low percentage of normal findings indicates that computed tomography is being judiciously applied in this clinical setting, thereby maximizing its diagnostic value and minimizing unnecessary radiation exposure.

Overall, the findings affirm that abdomino-pelvic computed tomography has become an essential component of modern radiological practice in tertiary healthcare institutions like the University of Benin Teaching Hospital. It supports evidence-based clinical decision-making, facilitates early

disease detection, and enhances treatment planning. The study further emphasizes the need to strengthen computed tomography imaging infrastructure, promote continuous professional training, and encourage early screening initiatives, particularly for hepatic and malignant diseases, to improve diagnostic outcomes and patient care in Nigeria and similar resource-limited settings.

5.4 RECOMMENDATIONS

1. **Enhance Early Screening for Hepatic Diseases:** Given that liver-related abnormalities such as hepatomegaly, cirrhosis, and primary liver cell carcinoma were the most frequent computed tomography findings, there is a pressing need for the establishment of routine screening programs for hepatic diseases. Early detection through ultrasound, biochemical tests, and, where necessary, computed tomography imaging will enable timely intervention, reduce disease progression, and improve overall patient outcomes in adults at risk of liver pathology.

2. **Improve computed tomography Infrastructure and Accessibility:** The importance of computed tomography in diagnosing abdomino-pelvic pathologies highlights the need for increased investment in imaging infrastructure. Government and hospital administrators should ensure the availability of modern multi-detector computed tomography scanners, stable power supply, and adequate maintenance services. Expanding computed tomography access beyond tertiary hospitals to regional and secondary facilities will help reduce patient delays, travel costs, and diagnostic backlog.

3. **Promote Clinician; Radiologist Collaboration:** Effective communication between referring clinicians and radiologists is vital for improving diagnostic accuracy and optimizing patient management. Regular interdisciplinary meetings, joint case reviews, and feedback sessions

should be implemented to ensure that computed tomography requests are appropriately justified, and imaging results are correctly interpreted in the context of clinical findings. This collaboration will enhance the quality of radiological practice and foster evidence-based healthcare delivery.

4. Encourage Continuing Education in Radiologic Practice: Continuous professional development for radiographers, radiologists, and referring physicians is necessary to maintain up-to-date knowledge of computed tomography technology, radiation safety, and emerging diagnostic techniques. Workshops, seminars, and refresher courses should be organized to enhance competence, improve image interpretation skills, and promote adherence to international best practices in computed tomography utilization.

5. Strengthen Public Awareness and Early Health-Seeking Behaviour: Public health campaigns should be intensified to educate communities on the importance of early medical consultation for abdominal symptoms such as pain, swelling, or unexplained weight loss. Increasing awareness about the availability and benefits of CT imaging can encourage timely diagnosis and reduce the burden of late-stage diseases, particularly liver and oncologic conditions that dominate CT findings.

6. Support Research and Data Sharing: The findings of this study underscore the value of radiologic research in identifying regional disease trends. Continuous research efforts should be supported through institutional funding and collaboration between medical centers. Establishing a centralized database for computed tomography findings across hospitals would facilitate data sharing, epidemiological surveillance, and evidence-based policy formulation in radiology and public health planning.

Limitation of the Study

This research was a hospital-based retrospective study that utilized existing patient records from the Radiology Department of the University of Benin Teaching Hospital. Consequently, the results may not accurately reflect the general adult population in Nigeria, as only individuals referred for computed tomography were assessed. This approach introduces possible selection and referral bias, since patients with less severe conditions may have been evaluated with alternative imaging modalities such as ultrasound or managed clinically without undergoing CT examination.

Additionally, the study sample consisted of 105 patients. While this number was sufficient for descriptive analysis, it restricts the generalizability of the findings to other tertiary health institutions or geographical regions within Nigeria. Conducting a larger, multi-centre study would likely yield more representative and nationally applicable results regarding abdomino-pelvic CT findings.

Furthermore, the study relied on radiologists' documented reports rather than independent re-assessment of the CT images by the researcher. Differences in reporting styles, diagnostic focus, and potential inter-observer variability among radiologists may have affected the classification and interpretation of the findings.

Suggestion for Further Studies

Future studies should adopt a multi-centre, prospective design involving hospitals across different regions, with standardized data collection and correlation of CT findings with laboratory, histopathological, and surgical outcomes, while also comparing CT with other imaging modalities such as ultrasound and MRI to assess diagnostic accuracy and cost-effectiveness, and placing particular emphasis on disease-specific evaluations, especially hepatic, oncologic, and trauma-related abdomino-pelvic conditions.

APPENDIX I: Data capture sheet

S/N	ID	Age (yrs)	Indication	Findings (Radiologist Report)

APPENDIX II: Ethical Approval Letter

HEALTH RESEARCH ETHICS COMMITTEE (HREC)

UNIVERSITY OF BENIN TEACHING HOSPITAL
P.M.B. 1111 BENIN CITY NIGERIA Telephone: 052-600418 Website: ubth.org

CHIEF MEDICAL DIRECTOR Prof. Darlington E. Obaseki
E-mail: darlobaseki@gmail.com

DIRECTOR OF ADMINISTRATION Jim Uwadie, Esq

CHAIRMAN Prof. (Mrs.) Antoinette N. Ofili

HREC OFFICE:
Committee email: ubthresearchethics@gmail.com
Registration Number: NHREC-UBTH-HREC/24/12/2022B

PROTOCOL NUMBER: ADM/E 22/A/VOL.VII/2025/205

PROPOSAL TITLE: "COMMON FINDINGS IN ABDOMINO-PELVIC COMPUTED TOMOGRAPHY EXAMINATION IN NIGERIAN ADULTS (A CASE STUDY OF THE UNIVERSITY BENIN TEACHING HOSPITAL)"

PRINCIPAL INVESTIGATOR(S): IYENGUMWENA VERA OSATOHAMWEN

DEPARTMENT/INSTITUTION: DEPARTMENT OF RADIOGRAPHY, SCHOOL OF BASIC MEDICAL SCIENCES, UNIVERSITY OF BENIN, BENIN CITY, EDO STATE

DATE CONSIDERED: AUGUST 20TH, 2025

DECISION OF THE COMMITTEE: APPROVED


THIS APPROVAL DATES 20/8/2025 TO 19/8/2026. IF THERE IS DELAY IN STARTING THE RESEARCH, PLEASE INFORM THE HREC SO THAT THE DATES OF APPROVAL CAN BE ADJUSTED ACCORDINGLY


REMARK:

CHAIRMAN: PROF. (MRS) A.N. OFILI

SUPERVISOR (S): AKPOBASAHAAN E.A. (DR)

DECLARATION BY INVESTIGATOR(S):
PROTOCOL NUMBER (please quote in all enquiries)
Note that no participant accrual or activity related to this research may be conducted outside of these dates. All informed consent forms used in this study must carry the HREC assigned number and duration of HREC approval of the study. In multiyear research, endeavor to submit your annual re-port to the HREC early in order to obtain renewal of your approval and avoid disruption of your research. No changes are permitted in the research without prior approval by the HREC except in circumstances outlined in the Code. The HREC reserves the right to conduct compliance visit your research site without previous notification

Signature & Date: 



ubthresearchethics@gmail.com

Registration Number: NHREC/24/01/202

REFERENCES

- Adama, A., Issa, S. M. & Hassan, I. Y. (2024) 'Abdominal masses: diagnostic value of imaging and surgical outcome in a tertiary hospital', *Journal of Surgery and Clinical Practice*, 9(2), pp. 45–54.
- Adekunle, O. J., Musa, T. I. & Bassey, E. O. (2024) 'Justification and optimization of CT scan usage in low-resource settings', *West African Journal of Radiology*, 31(1), pp. 12–20.
- Adeyanju, A. O. (2022) 'Spectrum of abdomino-pelvic diseases in Nigerian adults: implications for imaging practice', *Nigerian Medical Journal*, 63(3), pp. 155–162.
- Aklan, A. Y. & Mikhlafy, M. A. (2018) 'Comparative advantages of CT over ultrasound in abdominal imaging', *European Journal of Radiology Open*, 5, pp. 72–79.
- Akagbue, P. C., Eze, M. C., Onwuegbuna, A. N. & Okechukwu, O. O. (2023) 'Computed tomography urography findings among adult patients in a tertiary hospital in Nigeria', *African Journal of Urology and Radiologic Sciences*, 4(1), pp. 33–41.
- Chaudhry, A. N., Patel, R. K. & Gupta, V. S. (2023) *Clinical anatomy of the abdomen and pelvis*. 2nd edn. New York: Springer.
- Chukwu, C. E., Nwobodo, N. C., Ugwu, J. O. & Nnamani, I. M. (2021) 'Patterns of abdomino-pelvic CT findings in a Nigerian tertiary hospital', *Nigerian Journal of Clinical Imaging*, 8(2), pp. 89–97.
- Ezechukwu, F. O. (2020) 'Review of CT utilization and diagnostic outcomes in Nigerian tertiary centres', *African Radiology Review*, 6(1), pp. 22–29.

Filippone, A., Cianci, R., Romano, S. & Rengo, M. (2015) 'Advances in multi-detector CT: applications in abdominal imaging', *Insights into Imaging*, 6(3), pp. 267–282.

Goyal, M. P. (2024) 'Emerging trends in CT scan applications for abdominal pathologies in Sub-Saharan Africa', *International Journal of Radiologic Research*, 12(1), pp. 55–64.

Hassan, I. Y., Sulaiman, I. S. & Garba, M. T. (2021) 'Spectrum of abdominal CT findings among adults in Aminu Kano Teaching Hospital', *Sahel Medical Journal*, 24(2), pp. 87–93.

Hodler, J., Kubik-Huber, R. & von Schulthess, G. K. (2018) *Computed tomography and magnetic resonance imaging of the whole body*. 6th edn. New York: Springer.

Hsieh, J. & Flohr, T. (2021) *Computed tomography: principles, design, artifacts, and recent advances*. 3rd edn. New York: Academic Press.

Mollura, D. J., Lungren, M. P. & Kim, R. Y. (2020) *Radiology in global health: strategies, implementation, and applications*. 2nd edn. Cham: Springer.

Morani, A. C., Gee, M. S., Dillman, J. R. & Towbin, A. J. (2020) 'Current applications of CT in abdomino-pelvic pathology', *Radiologic Clinics of North America*, 58(3), pp. 499–515.

Olayinka, O. B., Adebayo, K. A. & Bello, R. L. (2022) 'A retrospective analysis of abdomino-pelvic CT examinations in Lagos University Teaching Hospital', *West African Journal of Radiology*, 29(1), pp. 13–22.

Parham, D. M., Omidiji, O. O. & Akinola, R. A. (2015) 'Barriers to evidence-based radiologic practice in resource-limited environments', *African Health Sciences*, 15(4), pp. 1211–1218.

Practice Parameter (2016) *Practice parameter for performing and interpreting computed tomography (CT)*. Reston, VA: American College of Radiology.

Romans, L. E. (2011) *Computed tomography for technologists: a comprehensive text*. Philadelphia: Wolters Kluwer/Lippincott Williams & Wilkins.

Sutton, R. T., Thomas, J. E. & Ogboye, V. S. (2020) 'Clinical decision-making and diagnostic precision in radiology practice', *British Journal of Radiology Practice*, 93(1113), pp. 1–8.

Triantopoulou, C., Van der Molen, A. J., Tsili, A. C. & Daskalogiannaki, M. (2013) 'Abdominopelvic actinomycosis: CT features and diagnostic challenges', *Abdominal Imaging*, 38(5), pp. 984–992.

Valtis, D. J., Akintoye, O. & Nwosu, O. C. (2016) 'Evidence-based radiology in developing nations: bridging the knowledge gap', *Global Health Imaging Review*, 2(1), pp. 10–18.

Wright, A. C. & Burns, P. E. (2022) *Anatomy and physiology of the abdomen and pelvis for radiographers*. Oxford: Oxford University Press.

Yunusa, M. A., Sani, A. M. & Garba, M. I. (2013) 'Abdominal helical CT findings in a tertiary hospital in Northern Nigeria', *Nigerian Journal of Clinical Practice*, 16(4), pp. 512–518.