

**ANTIFERTILITY ACTIVITY OF N-HEXANE EXTRACT OF BI- HERBAL  
FORMULATION OF *Carica papaya* AND *Vernonia amygdalina* LEAVES (VERCARIM)  
ON LABORATORY MICE.**

**BY**

**Aisosa Sandra IGBINEDION (MISS)  
(LSC LSC1602371)**

**UNIVERSITY OF BENIN,  
BENIN CITY.**

**NOVEMBER, 2022**

**ANTIFERTILITY ACTIVITY OF N-HEXANE EXTRACT OF BI- HERBAL  
FORMULATION OF *Carica papaya* AND *Vernonia amygdalina* LEAVES (VERCARIM)  
ON LABORATORY MICE.**

**BY**

**Aisosa Sandra IGBINEDION (MISS)**

**(LSC LSC1602371)**

**A PROJECT REPORT SUBMITTED TO THE DEPARTMENT OF SCIENCE  
LABORATORY TECHNOLOGY, FACULTY OF LIFE SCIENCES, UNIVERSITY OF  
BENIN, BENIN CITY, IN PARTIAL FULFILLMENT OF THE REQUIREMENTS FOR  
AWARD OF THE DEGREE OF BACHELOR OF SCIENCE (B.Sc HONOURS) DEGREE  
IN SCIENCE LABORATORY  
(PHYSIOLOGY AND PHARMACOLOGY)**

**NOVEMBER, 2022.**

## CERTIFICATION

This is to certify that this research project was carried out by Aisosa Sandra IGBINEDION (Miss) with matriculation number LSC1602371 for the Department of Science Laboratory Technology Faculty of Life Sciences, University of Benin, Benin City.

---

**Dr. (Mrs.).O. E. Obaro-Onezeyi**  
*(Project supervisor)*

---

**Date**

---

**Prof. F.I. Obahiagbon**  
*(Project coordinator)*

---

**Date**

---

**Associate Prof. E. O. Oshomoh**  
*(Head of Department)*

---

**Date**

---

***External Examiner***

---

**Date**

## **DEDICATION**

This research project is dedicated to the Almighty God for His consistent supply of help and wisdom from the beginning of my study to the end.

## ACKNOWLEDGEMENT

My deep gratitude goes to my supportive, caring and dedicated project supervisor Dr. (Mrs.) O. E. Obaro-Onezeyi and her husband Dr. P. O. Obaro for the close monitoring and involvement throughout the period of this study. I am also grateful for your patience during the collation of data analysis of all data collected and corrections of my project write up during the course of this research project, I want to say a big thank you.

My heartfelt gratitude goes to my highly esteemed parents, Late DSP. M.S. Edenabohen IBGINEDION of blessed memory and my mum Mrs IGBINEDION, my siblings for their support and encouragement.

To my husband Mr. Favour IMHANGBE and other family members for their constant assistance and encouragement all through this project work and to my colleagues, thank you.

To my roommates, cousins, friends, and everyone that contributed to my project I really appreciate you all.

## TABLE OF CONTENTS

Title page	i
Certification	ii
Dedication	iii
Acknowledgement	iv
Table of contents	v
List of tables	viii
List of plates	ix
Abstract	x
<b>1.1 CHAPTER ONE</b>	<b>1</b>
INTRODUCTION	1
1.1.1 Background to the Study	
Background of the study	1
1.2 Statement of the Problem	2
1.3 Justification of the Study	2
1.4 Aim of Study	2
1.5 Objectives of Study	2
<b>2.1 CHAPTER TWO</b>	<b>3</b>
2.1.1 Description of <i>Vernonia amygdalina</i> DEL	4
2.1.2 Ethnomedicinal uses of <i>Vernonia amygdalina</i>	
2.2 Description of <i>Caricapapaya</i> LINDL	5
2.2.1 Ethnomedicinal Uses of <i>Caricapapaya</i> LINDL	6
2.3 sexual changes in female mammals	9

2.3.1 Estrogens	9
2.3.2 Estrus cycle in mammals	11
2.3.3 The mouse estrus cycle	11
2.3.4 Divisions of the estrus cycle	12
<b>3.1 METHODS</b>	14
3.1.1 Collection of Plant Samples	14
3.1.2 Preparation of Plant Samples	15
3.2 Female Fertility Study	15
3.2.1 Hormonal assay	16
3.3.1 Determination of Estrus Cycle	
3.2 Female Fertility Study	16
3.2.1 Hormonal assay	16
3.2.2 Estrogenicity Study	16
3.2.3 Determination of Estrus Cycle	16
3.3 Data Analysis	17
<b>4.1 CHAPTER FOUR</b>	18
4.1.1 Results	18
4.1.2 Estrogenicity Study	18
5.1 Chapter five	23
5.1.1 Discussion	23
5.2 Histology of mice uterus after administration of N-hexane extracts of Vercarim	24
5.3 Conclusion / Recommendations	24

5.4 Findings	25
5. 5. Contribution to knowledge	25
Appendix	29

## LIST OF TABLES

- |     |   |    |
|-----|---|----|
| 4.1 | Effect of N-hexane extract of vercarim on hormonal assay            | 20 |
| 4.2 | Effect of N-hexane extract of vercarim on body mass indexes of mice | 21 |

## LIST OF PLATES

1.1 <i>Vernoniaamygdalina</i> DEL	4
1.2 <i>Carica papaya</i> LINDL	8
4.3 Effect of vercarim on Mice Uterus	19

## ABSTRACT

Over population has become a problem worldwide thus the need for drugs with fewer side effects compared to known orthodox drugs. At present there are reports from pregnant women who used the bi-herbal formulation during early pregnancy and noticed that it caused abortion, thus the need to scientifically investigate the safety of the bi-herbal formulation of *Carica papaya* leaf and *Vernonia amygdalina* on pregnant and non-pregnant albino Wistar rats. The n-hexane extract of bi-herbal formulation of *Carica papaya* leaf and *Vernonia amygdalina* was administered to the female animals orally at the doses of 30, 60 and 120 mg/kg per day for 14 days before mating and after confirmation of pregnancy respectively. Twenty four hours after the last administered dose, all the animals were sacrificed, uteri and blood were collected for examination and hormonal assay respectively. The results revealed that the reproductive hormonal assays (progesterone, estrogen, follicle stimulating hormones and luteinizing hormones) of tested animals significantly decreased within the tested period compared to the control. The pregnancy outcome results revealed there were signs of resorption and abortion in the uterus of the supposed pregnant rats compared with the control which had fetus in their uteri. This result revealed that the extract can be used as a contraceptive and an abortifacient agent.

## CHAPTER ONE

### 1.1 INTRODUCTION

#### 1.1.1 Background to the Study

The medicinal uses of bi-herbal formulations were introduced by Ayurvedic medicine. bi herbal formulation involves the use of two plant mixtures with various herbal products to eradicate diseases and their causes, restore balance and create a healthy lifestyle that is helpful in the prevention of recurrence of imbalance (Parasuraman *et al.*, 2014).

Vercarim is a combination of *Carica papaya* leaves and *Vernonia amygdalina* Del leaves

The individual plants of vercarim formulation had produced negative fertility outcome. Researchers have looked forward to get a better anti-fertility effect from the use of the formulated bi-herbal formulation (Chinaka *et al.*, 2019; Igwe and Okafor, 2015). The Efficacy studies on the properties of aromatic plants have been progressive internationally for numerous years to identify active and harmless substances in the fertility regulations and management of general health problems (Clarissa *et al.*, 2012). Results from these approaches have proven that chemicals of plant origins have limited side effects with phyto-therapeutic properties. In the possession of phyto-therapeutic effects, various species of plants remain useful as phytomedicine for the treatment and management of numerous disorders (Lawal *et al.*, 2009). Phytomedicines depend on the use of several herbal plants and other remedies for beneficial effects such as sexual arousal, improved sperm quality, regulate male and female fertility and improve chances of pregnancy, act as an antidepressant, anti-inflammatory and antidiabetic agents (Christian and Margaret, 2010).

## **1.2 Statement of the Problem**

Over the years, Africans especially Nigerians have battled with overpopulation problems, this has led to the discoveries of many infertility plants in-order to help regulate intervals of child birth and control the number of offspring birthed to the generation of married couples worldwide (Yeap *et al.*, 2020). The research is therefore designed to study the possible outcome of the use of vercarim the bi-herbal formulation on antifertility capacity of the bi-herbal formulation. the study has been imbued to enable proper scientific documentation of the poly herbal products for the first time.

## **1.3 Justification of the Study**

The recent interest in herbal drugs has grown with the advent of new culture “return to nature” a rational evaluating the potentials of some medicinal plant formulations as a remedy to eradicate over population, bring about child spacing between each child born to a couple and control the number of children born in a family.

## **1.4 Aim of Study**

This study aimed to evaluate the antifertility effect of the bi-herbal formulation on laboratory mice.

## **1.5 Objectives of Study**

The specific objectives of the study were to:

1. Assess the antifertility profile of the n-hexane extracts of vercarim formulation with reference to fertility female parameters.
2. Determine estrogenicity activity.

## **2.1**

## **CHAPTER TWO**

### **2.1.1 Description of *Vernonia amygdalina* DEL**

*Vernonia amygdalina* is a wooded shrub of about two to ten meters tall that, once sown, quickly regenerates. The leaves have petiolated shapes and an unpleasant bitter flavor of which its common name “Bitter leaf” springs up (Agbogidi and Akpomorine, 2019).

Among the most well-known plants that grow in Africa and Asia is indeed the bitter leaf, botanically classified as *Vernonia amygdalina*. It's the *Vernonia* species that is most frequently grown in gardens, that is about 1,000 species of shrub (Agbogidi and Akpomorine, 2019; Toyang and Verpoorte, 2013; Egharevba *et al.*, 2014 and Njanet *et al.*, 2018). The much more notable Asteraceae family species that has recently been researched in Africa is *Vernonia amygdalina*. (Ankit *et al.*, 2010; Nwaoguikpe, 2010; Farombi and Owoeye, 2011; Igweet *et al.*, 2015). Since *V. amygdalina* typically doesn't generate seeds, it's also typically grown through stem planting in tropical environments. This plant is majorly located in domestic areas and commercial plantation or forest (Yeapet *et al.*, 2020).

### **2.1.2 Ethnomedicinal uses of *Vernonia amygdalina***

Various regional names for *Vernonia amygdalina* exist and range from nation to nation. There have been theories linking the existence of tannins, glycosides, alkaloids, as well as saponins to the bitter flavor. These enabled it to be serves as a bittering ingredient as well as a hop replacement for the purpose of preventing microbiological contamination in beer production while lowering the malt integrity (Ankit *et al.*, 2010; 2011; Farombi and Owoeye, 2011).



Plate 1.1: *Vernonia amygdalina* DEL

Photo credit: Igbinedion Aisosa

## 2.2 Description of *Caricapapaya* LINDL


*Carica papaya*, sometimes known as pawpaw, is indeed a dicotyledonous, polygamous, as well as diploid plant (Agarwal *et al.*, 2016). The papaya is indeed a huge perennial plant that grows quickly. The plants are either female, male, or hermaphrodite (\*Sharma *et al.*, 2019). The papaya plant does have a 6–20 foot (1.8–6.1 m) tall, branchless, succulent, and soft woody trunk with a palm-like crown of foliage there at the top. The leaves were severely cut as well as lobed, and the trunk is scarred with scars from past leaf stalks. They cannot develop real bark (Adiaha and Adiaha, 2017). Mature leaves have deep, palmate lobes but are held upright by a smooth, hollow petiole. As the plant's circumference increases, the petiole scars on the leaves get larger (Nugroho *et al.*, 2017). Under the canopy of massive leaves, clusters of fruits hang from the trunk on short stalks. The fruit as well as flowers of papayas are produced at the same time every year. The fruit is considered to be ripe when its texture is soft (similar to or somewhat softer than an avocado) as well as its skin has an amber to orange tint. Size and form of the fruit that resembles a melon vary (Roshan *et al.*, 2019). Fruits range in form from oval to almost pyriform to elongated club-shaped, measuring fifteen to fifty centimeter long, ten to twenty centimeter thick, and 9 kilogram in weight. Semi-wild (naturalized) plants have stems that are 2.5–15 cm tall, as well as the fruit skin is stiff and waxy. When a fruit ripens, its skin begins to change from green to yellow-orange to red and contains a greater quantity of white latex, becoming aromatic, juicy, but also delicious (Maisarahet *al.*, 2019). There at leaf axil, the fruit is suspended by short, thick peduncles (Roshan *et al.*, 2019). Fruit's changing exterior color is a sign of maturity, and so this shift is thought to be mostly caused by an elevation in carotene concentration and a reduction in chlorophyll. Fruit's red flesh color showed how much lycopene was present (Maisarahet *al.*, 2019). Pawpaw, sometimes known as *Carica papaya*, is indeed a tropical lozenge fruit with just a rich orange pulp that is usually found in orange-red, yellow-green, as well as yellow-orange hues.

Fruit, roots, bark, peel, seeds, and pulp from the entire plant are recognized to have therapeutic benefits in addition to being delicious as well as healthful. The abundance of vitamins A, B, and C as well as the antiviral, antifungal, and antibacterial activities of papain as well as chymopapain are responsible for the papaya's numerous health advantages.

### **2.2.1 Ethnomedicinal Uses of *Caricapapaya* LINDL**

Unripe fruit contains papain, a protein that helps with the digestion of protein-rich foods in acidic, alkaline, and neutral environments. The papaya fruit has a good nutritional value and just 32 calories per 100 grams of mature fruit. This fruit resembles berries and has parietal placentation (Noshad and Anjum, 2018). Papaya has a number of beneficial properties, including defense against helminthic, protozoan, bacteria, fungal, viral, inflammatory, sickling, neuroprotective, diuretic, abortifacient, hypoglycemic as well as hypolipidemic, antihypertensive, wound repair, anticarcinogenic, and antifertility effects. Ripe papayas are applied topically to chronic skin lesions to enhance granulation, healing, and odor control. Green papaya is utilized to treat intestinal helminthiasis, jaundice, hypertension, diabetes, and malaria (Maisarahet al., 2019). Additionally, it prevents cancer, prevents strokes, and lowers blood cholesterol (Arlianaet al., 2015). Polysaccharides, minerals, enzymes, proteins, glycosides, lipids as well as oils, saponins, flavonoids, plus sterols are just a few of the phytochemicals found in carica papaya. As nothing more than a dehydrated and crystallized fruit, it is frequently utilized in pies, sherbet and salad preparation, jellies, jams, beverages, and ice creams. Vitamin C, A, Calcium, Riboflavin, Folate, Thiamine, Niacin and Fibre are all found in abundance in papaya (Adiaha and Adiaha, 2017). It also aids in meat tenderization. Furthermore, papaya increases the body's ability to take in iron. Papaya fruit contains the heart-depressant alkaloid carpaine (Adiaha and Adiaha, 2017). Flowers have emmenagogue, febrifuge, as well as pectoral effects and are

employed to treat jaundice (Roshan, 2019; Sharma et al., 2019). The papaya flower has received little investigation; nonetheless, male flowers are examined for their capacity to produce herbal tea that can be consumed as a nutritional supplement (Bergonio and Perez, 2016). The phytochemical found in *C. papaya* peel isolates could be effectively used to create formulations for biocides or insecticides. The peel of the *C. papaya* may have larvicidal effects on *Aedes aegypti* (Hayatieet al., 2015). Additionally, papaya peel has healing effects for cuts (Parni and Verma, 2019). In Australia, their leaves are utilized to treat cancer, abortion, beriberi, colic, and fever. Traditional therapies for conditions like jaundice, malaria, dengue, and immunosuppressive and antiviral activity involve papaya leaves (Bergonio and Perez, 2016; Kavimandan and Saraf, 2016). Young leaves are abundant in phenolic compounds (ferulic acid, caffeic acid, chlorogenic acid), flavonoids (kaempferol and myricetin), alkaloids (carpaine, pseudocarpaine, dehydrocarpaine I and II), and cynogenetic chemicals (benzylglucosinolate). They possess therapeutic qualities such as anti-inflammatory, hypoglycemic, anti-fertility, wound-healing and anticancer actions (Yogirajet al., 2019). In East Indies, young leaves are eaten like spinach and are employed in preparation of food. Papaya leaves possess defensive capacities against oxidant, cancer, bacteria, and analgesic properties and are employed as a tonic treating cardiovascular events and as a stomach discomfort remedy.



**Plate1.2:** *Carica papaya* LINDL Photo credit: Igbinedion Aisosa

### **2.3 SEXUAL CHANGES IN FEMALE MAMMALS**

In most mammal's estrus is accompanied by heightened sexual excitement (oestrous comes from the greek word oistros meaning 'mad desire') and the animal is described as being 'on heat'. At this stage the female may produce various secretions which act as pheromones, inducing sexual activity in the male. This ensures that the female is impregnated at the right time (Roberts, 1986). The period of time during which the females can be successfully impregnated is limited to around the time of ovulation. This period is called the sexual cycle, or alternatively the menstrual cycle (in humans) or estrus cycle (in other mammals). In some species, rabbits for example, this is made even more sure by the fact that ovulation is delayed until mating occurs. In humans, and other primates however, no such safeguards exist; there is no evidence of increased sexual awareness at the time of ovulation, and it is largely fortuitous as to whether or not copulation takes place at the right time (Adaay *et al.*, 2013c).

### **2.3.1 ESTROGENS**

A group of steroid hormones known as estrogens are primarily responsible for the regulation of female sex organ response and reproduction. The significant natural estrogens are 17  $\beta$ -estradiol, estrone, and estriol.

The biogenic form 17  $\beta$ -estradiol is the most powerful. The ovary is the site of estrogen biosynthesis. The terms coumastrans, lignans, and myoestrogens refer to the flavones, flavanones, as well as isoflavanoids that are obtained from plants. When these substances engage with the estrogenic receptor, they produce estrogenic properties such as the uterotrophic effect. This causes sterility or disrupts normal effects arising in farm animals that graze on resources of plants strong in phytoestrogens (Jainu *et al.*, 2015). Estrogens are necessary for a female to develop normally. They promote secondary sexual traits as well as the growth of the uterus, uterine tube, and vagina. These also contribute significantly towards

the formation of the endometrial lining as well as promote the production of enzymes as well as growth factors, which promote uterine expansion and specialization. The sensitive estrogen and progesterone ratio necessary for the insertion of the blastocyte with in endometrium is likewise altered by given estrogens. The plasma of a female human only contains -estradiol (E2), estrone (E1), and estriol in considerable amounts (E3). -Estradiol is the main estrogen released by the ovaries. Additionally produced in tiny portions is estrone. Additionally, estrogens stimulate the development of the hormone receptors required for the interacting of other hormones. The stimulation of intracellular receptors is the main mechanism through which estrogens exert most of their effects (Paranjape,1994). Estriol is already an oxidative substance produced mostly in the liver from estradiol as well as estrone. Estrone and estriol have an estrogenic potency of 12 and 80 times, respectively, that of -estradiol (Guyton,1986). Nevertheless, there is an additional form of estrogen (E4) that is only created in pregnancy and therefore is called as sterol (Ghosh,2018). Estrogen and progesterone are the two distinct ovarian hormones. Both ovarian hormones are crucial throughout pregnancy; progesterone is mostly released by the corpus luteum while estrogen is primarily produced by developing follicles. When a pregnancy develops, the normal ovarian cycle is interrupted, as well as the placenta and corpus luteum produce the hormonal relaxing, which maintains uterine quiescence which protects the pregnancy from ending prematurely (Jainuet *al.*, 2015).

### **2.3.2 ESTRUS CYCLE IN MAMMALS**

Estrus in human females occurs roughly halfway among one menstrual cycle and the following. and given that the reproductive cycle lasts 28 days, a woman may ovulate 12–13 times throughout the duration of a year. Only a few additional mammals exhibit such a low frequency.

The estrous cycle lasts just around three weeks, sometimes in large mammals like cows, and so it happens every four to five days in small mammals including rats and mice. Most mammals don't really menstruate (Adaayet al., 2013b), therefore its sexual cycle is typically called to as the theestrus cycle.

### **2.3.3 THE MOUSE ESTRUS CYCLE**

The renowned work by dates the understanding of the mouse estrous cycle to (Adaay and mosa, 2012 b). Unless interrupted by pregnancy, pseudo pregnancy, or by other events such as diseases, micenormally prone to exhibit estrous symptoms, including as mating activity, around 4 to 5 days. The mouse therefore is a polyestrous mammal. Individual cycles are actually complexes of related secretory, anatomical, and behavioral cycles, the rhythmic interaction of pituitary and ovarian hormones is fundamental and which, in their totality, have the function of insuring fertilization. The cyclic alterations in the ovary, which then in turn reflect changed hypothalamus activity including alterations in gonadotropin production, directly contribute to the periodicity of estrus seen in mature females. The issue of the fundamental cause of such rhythmicity is poorly known, as well as the mouse has only been used in a small amount of study to address this issue. It appears that the hypothalamus, that connects only with anterior pituitary via a portal system, holds the secret to cyclic reproduction activity. The anterior pituitary secretes the protein known as FSH, which stimulates the formation of follicles.

LH (Luteinizing Hormone), additional anterior pituitary protein, aids with in mature follicle's final implementation and makes it easier for the FSH-primed follicle's interior theca cells to produce estrogens. The hypothalamus's continued secretion of LH causes the follicle to burst, which leads to ovulation. All through the follicular growth phases, the ovary also produces tiny amounts of progesterone, another gonadal steroid. By increasing LH release, progesterone, in

short dosages, encourages ovulation. As a result, the gonadal hormones created throughout follicular development work on the hypothalamus to promote the production of LH and ovulation while inhibiting the secretion of further FSH. In the mouse, mating induces the functional growth of the corpus luteum; in the absence of mating, gonadal hormone titers decline, permitting the succession of a new cycle.

Cyclic action within hypothalamus, which would be mirrored in LH release, is regarded to be the primary component for the periodicity of estrous events.

#### **2.3.4 DIVISIONS OF THE ESTRUS CYCLE**

Diestrus, proestrus, estrus, as well as metestrus are the only four phases that have been identified for the mouse estrous cycle; there may be as many as thirteen (Adedapo et al., 2017). The latter approach has a single diestrus stage, four proestrus stages, two estrus stages, and six metestrus stages. This part will rely on a five-stage explanation of the cycle because the process is continual and it is uncommon to divide the cycle into so many phases (Bulletti, 2000). The first two phases (proestrus and estrus) are anabolic phases in which the genital tract actively grows in a number of locations.

They end with ovulation and, in cases when mating takes place, in conception. Metestrus-1 and -2, the third and fourth stages, are catabolic stages marked by genital tract degeneration. Diestrus, the final (or first) stage, is a time of dormancy or slow growth.

Examining vaginal smears makes it simple to trace the cycle. Vaginal smears' cellular characteristics reveal changes in the makeup of the vaginal epithelium, which then in turn have an impact on estrogen and proceed in a consistent and predictable manner throughout the cycle. Leukocytes, cornified epithelial cells, as well as nucleated epithelial cells are indeed the three types of cells that can be seen in vaginal smears. There are several ways this fundamental pattern

might be altered. The smear can have epithelial cells with karyolytic nuclei and dark-staining cytoplasm as estrus approaches. There are also cells that fall somewhere between cornified as well as nucleated epithelial cells. It ought to be noticed that clusters or sheets of cornified cell are frequently seen in the smear denoting the end of estrus (Capasso et al., 2019). Bulbul et al. conducted an experimental study to determine how the proportion of estrogen to progesterone affected the vaginal smear (2020). No matter how much estrogen is administered, an adequate dosage of progesterone will cause an estrous smear to turn into diestrus. Only a modest amount of progesterone is required to convert an estrous smear to diestrus, while a somewhat high dose is required to block the vaginal response to estrogen. Those two ovarian hormones, in particular estrogen, are responsible for uterine and vaginal alterations during the estrous cycle. Adrenocortical neoplasms, which can have complex endocrine effects, are what cause certain estrus-like cycling in gonadectomized females (Christian and Margaret, 2010). Similar to the vagina, the uterus experiences a number of anabolic as well as catabolic changes throughout the estrus cycle, though they are considerably less noticeable. Due to the activation of the uterine glands during proestrus and estrus, the uterus appears swollen overall. Late estrus marks the beginning of the distension's decline, while diestrus marks the uterine wall's collapse and anemia. The uterus is fairly hydrated during proestrus and estrus, with wet and dry weights being low at diestrus as well as highest during proestrus (Balkar et al., 1994). When in proestrus, the glycogen content is highest. In estrus, the uterine epithelium is made up of low columnar cells (Caulfield and Birdsall, 1998). Degenerative mechanisms emerge in metestrus-1. The basal surfaces of the epithelial cells as well as the superficial stroma are included in a pink-staining strip that emerges from the basement membrane. The epithelium develops vacuolar degeneration and loses its distinct architecture. In the vicinity of the basement membrane, leukocytes are seen. The

epithelium's degeneration is further advanced in metestrus-2, and practically all of the epithelial cells are gone (Oshomoh and Obaro-Onezeyi, 2020). Leukocytes are plentiful and cell walls are no longer discernible at this point. The uterine glands are not very active. The start of regeneration processes denotes the commencement of diestrus. The ultrastructure of the mouse uterine epithelium was investigated by Peter and Gandhi (2017), who verified that estrus is the time of highest secretory activity. For mice in estrus, additional estrous cycle correlates have been reported (Omale and Ugwu, 2011). Obaro and Oshomoh (2019) identified alterations in the oviduct connected with the estrous cycle as minor variations in body weight and reproductive system organ mass. Estrus causes a little relaxing of the pubic symphysis. According to Omale and Ugwu (2011), the estrous cycle and skin mitotic activity are correlated. Injecting PMS (Pregnant Mare Serum) did not alter the ovarian sensitivity during the estrous cycle, according to Green (1957). In order to determine whether the plant has a pro-fertility or anti-fertility impact on the female sexual cycle and to determine if it would be beneficial as an antifertility agent, this study examined the effects of Vercarima biherbal preparation on adult female mice.

### **3.1 METHODS**

#### **3.1.1 Collection of Plant Samples**

Plant samples were collected between March and December 2017 from Iguobazuwa village of Ovia North East local Government Area of Edo State Nigeria. The plants were authenticated by Dr. H. Akinnibosun of the Department of Plant Biology and Biotechnology, Faculty of Life Sciences, University of Benin, Benin City. The plant samples were first air-dried at ambient temperature for 14 days and then dried at 104°F (40°C) with an oven for an hour. The dried samples were then reduced to fine particles of powder with the aid of a grinder that is electrically powered and kept in airtight storage containers for subsequent usage.

### **3.1.2 Preparation of Plant Samples**

Ten kilograms (10 kg) each of the powdered samples of *Vernonia amygdalina* leaves and *Carica papaya* leaves in ratio 1:1:1 was extracted with N-hexane solvent using the Soxhlet apparatus. The resulting crude extracts were then concentrated to dryness in a vacuum at 40<sup>0</sup>C with a rotary evaporator. The concentrates were dried completely in an oven at 40<sup>0</sup> C. The yield percentages were obtained concerning used dried powder for extraction. The specific weight of extracts was dissolved in distilled water to obtain a stock solution from which dilutions were made and calculated doses were administered to the animals during the experimental procedures.

## **3.2 Female Fertility Study**

### **3.2.1 Hormonal assay**

Testosterone (TST), progesterone (PGST), prolactin hormone, follicle stimulating hormone (FSH), leutenizing hormone (LH), Estrogen 2 hormone (E2), were quantitatively analysed using Eliser kit USA. The total TST, FSH, Lu and E2 in the serum of male and female Wistarrats were determined by automated methods

### **3.2.2 Estrogenicity Study**

#### **3.2.1 Determination of Estrus Cycle**

Estrus cycle was determined between the early hours of 7- 8 am using the vagina smear method. Only mice that attained three consecutive estrus circles were used for the study. The Mice that did not attain three (3) consecutive estrus, within the period of 30 days were removed from the study (Nishant *et al.*, 2015).

Ganado intact mature female mice weighing 20-25 g were randomly allotted into five groups. The test groups weretreated with 10, 30,60 and 120 mg/kg respectively of vercarim. Twenty-four

hour after the 14 days treatment all the mice were sacrificed, ovaries and uterine weight variations were determined. The relative weight of uterine mass was determined, serum hormonal levels of fertility hormones such as LH, FSH and E2 cell levels were evaluated (Aday et al., 2013a).

### **3.3 Data Analysis**

Results from this experiment were provided as mean  $\pm$  SEM. Statistical analysis were carried out using graph pad prism 6 version software (UK). Comparisons between the control and treated groups were analysed by means of one-way ANOVA and, Dunnett's multiple comparisons test. \* = P <0.05, \*\* = 0.01 and \*\*\* = 0.001 were regarded as indicating significant differences

## **CHAPTER FOUR**

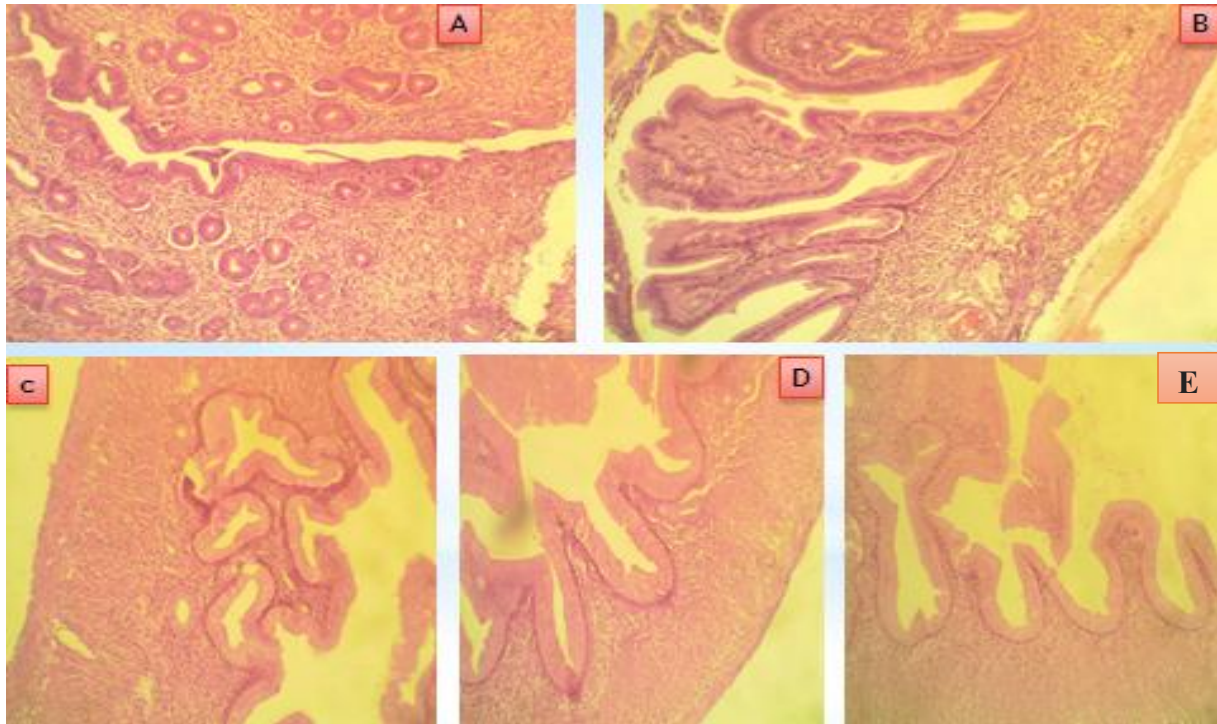
### **4.1.1**

### **RESULTS**

#### **4.1.2 Estrogenicity Study**

The effect of N-hexane formulated extract of vercarim at on Matured female Mice weighing 25-30 g administered 10, 30,60 and 120 mg/kg of extracts for 14 days revealed significant increased reproductive organ mass significant with P-values at  $*P<0.05$ (Table 4 .1 and 4.2).

Endometrial epithelia height (EH), Endometrial epithelia lining (EL), Endometrial glands (EH)and (pp) Polyploids (Plate 1, A to E).



**Plate 4.3:** Effect of vercarim on Mice Uterus

A = Control

B = Tamoxifen 10 mg/kg

C = Vercarim 30 mg/kg

D = Vercarim 60 mg/kg and

E = 120 mg/kg

**Table 4.1:** Effect of N-hexane extract of vercarim on hormonal assay

The effect of vercarim on mice treated revealed that there were significant decreases of all the reproductive hormonal parameters assayed.

<b>Treatment</b> <b>mg/kg</b>	<b>Testosterone</b>	<b>LH</b>	<b>FSH</b>	<b>EST2</b>
<b>control</b>	20±0.06	24±0.12	22±0.15	20±0.51
<b>Vercarim30</b>	9.7±0.38 <sup>**</sup>	0.9±0.03 <sup>*</sup>	0.2±0.06 <sup>***</sup>	0.7±0.38 <sup>**</sup>
<b>Vercarim60</b>	5.9±0.18 <sup>***</sup>	0.1±0.05 <sup>***</sup>	0.2±0.92 <sup>**</sup>	2.9±0.18 <sup>***</sup>
<b>Vercarim120</b>	8.4±0.24 <sup>***</sup>	0.4±0.01 <sup>**</sup>	0.1±0.80 <sup>***</sup>	2.4±0.24 <sup>***</sup>

Values represent mean ± SEM. n = 6, \* = P≤0.05, \*\* = P≤0.01, and \*\*\* = P≤0.001 in assessment with the control group.

**Key:**

Vercarim = *Vernonia amygdalina* and *Carica papaya* leaves mixture.

**Table 4.2:** Effect of N-hexane extract of vercarim on body mass indexes of mice

The effect of vercarim on the body mass indexes of mice treated revealed that there were significant increases of all the body weight of treated mice.

Treatment (mg/kg)	Weight at day 0	Weight at day 7	Weight at day 14
Control	24.0±0.4	24.5±0.6	25.1±0.5
Tamoxipen 10	27.9±0.5	27.0±0.9*	26.7±0.3*
Vercarim30	25.5±0.3	26.3±0.1	26.6±0.8*
Vercarim60	25.6±0.2	25.7±0.7	28.0±0.2*
Vercarim120	25.0±0.5	25.8±0.8	26.4±0.1*

Values represent mean ± SEM. n = 6, \* = P≤0.05, \*\* = P≤0.01, and \*\*\* = P≤0.001 in assessment with the control group.

**Key:**

Vercarim = *Vernonia amygdalina* and *Carica papaya* leaves mixture.

## 5.1

## CHAPTER FIVE

### 5.1.1

### DISCUSSION

Histology of mice uterus after administration of N-hexane extracts of Vercarim.

The study carried out on reproductive parameters and histology of uterus of mice treated with various doses of bi-herbal the bi-herbal formulation revealed significant decrease in endometrial glands (EG) accompanied with polypoid formation and reproductive hormonal profiles such as testosterone, leuthenizing hormone, follicle stimulating hormone and estrogen (E-2). The results on pregnancy development showed abortifcent effect revealed by retardation of fetuses inutero.

The results from reproductive hormonal profile study showed significant decreases in E2 cells which was ascribed to the fact that Vercarim does not possess phytoestrogens such as steroids, alkaloids, glycosides, terpenoids and flavonoids contained which not may exist energetically at little or much absorption and functions as an antagonist to the E2 hormones and influences additional target tissues. It is well recognized that phytoestrogens can alter fundamental cell biology, which has an impact on cellular enzymes. The significant decrease in serum FSH, and LH level after oral administration of the biherbal formulated extracts of Vercarimcan be attributed to low plasma concentrations of estrogen, as high concentrations are expected occurring before and whereas the opposite was true during the early to late follicular phase estrogen peak. The pituitary is influenced by the late follicular phase, which increases the susceptibility of the LH-releasing system to GnRH. Despite this being still unknown, the high levels of estrogen may indeed encourage the hypothalamus to secrete more GnRH during the pre-ovulatory period (Shaw *et al.*, 2010). Furthermore, although restricted, pre-ovulatory progesterone production may exert great time on the estrogen-stimulated pituitary to boost the secretion of FSH as well as LH. The study resulted noteworthy reduction in level of serum in

FSH and LH in pro estrous phase of the estrous cycle; this may have affected ovulatory development. One way to express this is in the early follicular phase where FSH is abundantly released as well as late follicular phase LH level increases in relation to the increase in E2 levels which means that there was unexplainable decrease of FSH, LH and E2 level in the late ovulatory phase which means that there was need to increase estrogen level. Additionally, the present investigation discovered that the adverse feedback of E2 was mostly exerted on FSH release at the pituitary level, ostensibly leading to a decrease (Matikainen *et al.*, 1992).

### **5.3 CONCLUSION / RECOMMENDATIONS**

The present biological evaluation has shown that N-hexane extract of Vercarim formulated extracts of possess antifertility activity with effective doses ( $EC_{50}$ ) were obvious at 30,60 and 120 mg/kg, which exhibited anti-fertility effect on female fertility parameters. This research has also authenticated that Vercarim is an antifertility agent. The combinations present in Vercarim showed anti-fertility effect as expected when the individual plants are used singularly; correlating with the argument of Dr (Mrs) Obaro-onezeyi hence the reason why it is not used as a profertility agent. The biherbal formulated extract of Vercarim also showed convincing potentials for the management of diabetes, peptic ulcer, CNS, inflammatory disorders and pains. It is recommended that Vercarim should be used as an antifertility agent and subjected to clinical trials in contraception and family planning.

## 5.4 FINDINGS

The following are the findings from the study:

1. Vercarim was rich in phytochemicals useful in the treatment of various
2. Vercarim had ant-fertility potential
3. Vercarim significantly decreased female reproductive hormone
4. Toxicity study indicated that Vercarim was safe for consumption as there were no injurious effect to the ovary at all administered doses
5. The lowest - highest doses of 30 and 120 mg/kg of vercarimon male albino rats resulted in antifertility effect revealed by significant decrease LH, FSH, and E2 hormones as well as distortions in uterine morphology.

## 5. 5 CONTRIBUTION TO KNOWLEDGE

The following were the contributions to knowledge from this research:

1. The research has provided first hand scientific documentation of Vercarim as a potential antifertility agent.
2. The misconception thatVercarimis antifertility agent is here by corrected that the polyhedral product is a good sources anti-fertility agent.

## REFERENCES

- Adaay, M.H., Al-Dujaily, S.S., Ferial, K. and Khazzal F.K (2013a). Effect of aqueous extract of *Medicago sativa* Salvia officinalis mixture on hormonal, ovarian and uterine parameters in mature female mice. *Journal of Material Environmental Science*, **4** (4): 424-433.
- Adaay, M. H. and Mosa, A. A. (2012b). Evaluation of the effect of aqueous extract of *Tribulus terrestris* on some reproductive parameters in female mice. *Journal of Material*, **8**: 23-41.
- Adaay-Mohaisen, H., Saad, S. A. and Ferial, K.K. (2013c). Effect of Aqueous Extract of *Medicago sativa* officinalis Mixture on Hormonal, Ovarian and Uterine parameter in female mice *Journal of material and environmental science* 4(4), pp424-433.
- Adedapo, A. A., Abatan, M.O. and Olorunsogo O. (2017). Effect of some plants of the spurge parameters in rats. *Veterinarski*, **77**: 29 -38
- Adiaha MS and Adiaha MS (2017) Effect of Nutritional, Medicinal and Pharmacological Properties of Papaya (*Carica papaya* Linn.) to Human Development: A Review. *WSN* **67**(2): 238-249
- Agbogidi, O. M. and Akpomorine, M. (2019). Health and Nutritional Benefits of Bitterleaf (*Vernonia amygdalina* Del.). *International Journal of Applied Pharmaceutical Sciences and Biological Sciences*, **2**(3): 164–170.

- Ankit Saneja, Chetan Sharma, K.R. and Aneja, R. P. (2010). Bitterleaf as Local Substitute for Hops in the Nigerian Brewing Industry. *Journal of Pharmacia*. **2**(2): 208–220.
- Arliana F., Tunjung, Anindito W (2015). The flavonoids content in leaves and fruits of papaya (*Carica papaya* L.) var. *Journal of life sciences* **2**: 154-158.
- Bergonio KB, Perez MA (2016) The potential of male papaya (*Carica papaya* L.) flower as a functional ingredient for herbal tea production. *Indian journal traditional knowledge* **15**(1): 41-49.
- Bulletti, C., De Ziegler, D., Polli, V., Diotallevi, L., Del Ferro, E. and Flamigni, C., (2000). ‘Uterine contractility during the menstrual cycle. *Human Reproduction*, **15**: 81–89.
- Balkar Singh S. P., Sharma, R., Goyal, I. and Annals N.Y., (1994). *Journal of Academic Science*, Barik BR, Bhaumik T, Dey AK, Patra A, Chatterjee A. Premnazole (1976), an isolated alkaloid of *Premnaintegrifolia* L. and *Gmelinaarborea* L. with anti-inflammatory activity, *Fitoterapia*. **63**(4): 295–299.
- Bulbul, I.J., Nahar, L., Ripa, F.A. and Haque, O. (2020). Antibacterial, cytotoxic and antioxidant activity of chloroform, n-hexane and ethyl acetate extract of plant *Amaranthus spinosus*. *International Journal of Pharmacological Technique Resources*, **3**: 1675-1680
- Capasso, F., Cerri R, Morrica P., and Senatore F., (2019) Chemical composition and anti-inflammatory activity of an alcoholic extract of *Teucrium polium* L. *Italian Journal of Biology*, **59**:1639-1643.
- Caulfield M.P. and Birdsall N.J. (1998). Classification of muscarinic acetylcholine receptors. XVII. Pharmacological Review. *International Union of Pharmacology*, **50**:279–90.

Christian W, G. and Margaret. (2010). Utero Plants and Their Bioactive Constituent.

*Planta Medicine*,**30**:12-18.

Egharevba, C., Osayemwenre, E., Imieje, V., Ahomafor, J., Akunyuli, C., Udu-Cosi, A. A.,

Theophilus, O., James, O., Ali, I. and Falodun, A. (2014). Significance of Bitter Leaf (*Vernonia amgdalina*) In Tropical Diseases and Beyond: A Review. *Malaria Chemotherapy Control and Elimination*. **3(1)**:1–10.

Ekumankama, O. (2008). Nutrient Composition of indigenous vegetables (*Pterocarpus Soyaxii*,

*Pterocarpus Santallinoides* and *Gnetumafricanum*). *Nigerian Journal of Nutritional Science*. **29**:19-200

Farombi, E. O. and Fakoya, A. (2005), Free radical scavenging and antigenotoxic activities of natural phenolic compounds in dried flowers of *Hibiscus sabdariffa*. *Journal of Molecular Nutrition and Food Reservation*, **49**:1120-1128.

Farombi, E. O. and Owoeye, O. (2011). Antioxidative and Chemopreventive Properties of *Vernonia*

Ghosh, R., Patil, S.M. and Kadam, V.J. (2009a). *In vitro* antioxidant activity of methanol extract of stem bark of *Gmelina arborea* (Verbenaceae). *International Journal of Pharmaceutical Technology Research*, **4**:1408–1424.

Ghosh, S. and Suryawanshi, S.A. (2019b). "Effect of *Vincarosea* extracts in treatment of alloxan diabetes in male albino rats," *Indian Journal of Experimental Biology*, **39** (8): 748–759.

Igwe, K.Kalu, Ijeh I. and Okafor P.polycorp(2015). Action of contractile fraction of *Vernonia Aygdalina*Del on hormonal profile of estrogen and progesterone on Wistar rats, *Global research journal of science and Nature***1(2):1-5**

Jainu, M., Shyamala, Hl. and Devi, C.S. (2004). Antioxidant effect of methanolic extract of *Solanum nigrum* berries on aspirin induced gastric mucosal injury. *Indian Journal of Clinical Biochemistry*, **19**: 57-61.

Kavimandan B, Saraf M (2016) Studies on Biological Efficacy of Various Leaf Extracts of *Carica Papaya* L. International Conference on Global Trends in Engineering, Technology and Management pp: 510- 516. 41

Maisarah AM, Asmah R, Fauziah O, Analysis P. (2019). Antioxidant and Antiproliferative Activities of Different Parts of *Carica Papaya*. *Journal of Nutrition & Food Sciences***4(2)**: 1-7. 28.

Nishant, S., Akhilesh, S., Chauhan, SK., Gupta, SH., Bodakhe, D. and Prasad P. (2015). Antifertility Studies of Curcumin and Andrographolide Combination In Female Rats *Pharmaceutical Sciences*,**6**:12-19.

Njan, A. A., Adzu, B., Agaba, A. G., Byarugaba, D., Díaz-Llera, S. and Bangsberg, D. R. (2018). The Analgesic and Antiplasmodial Activities and Toxicology of *Vernonia amygdalina*. *Journal of Medicinal Food*. **11**(3): 574–81.

Nugroho A, Heryani H, Choi JS, Park HJ (2017) Identification and quantification of flavonoids in *Carica papaya* leaf and peroxynitrite scavenging activity. *Asian Pacific Journal Tropical Biomedicine***7**(3): 208-213.

Nwaoguikpe, R. N. (2010). The Effect of Extract of Bitter Leaf (*Vernonia amygdalina*) on Blood Glucose Levels of Diabetic Rats. *International Journal of Biology and Chemical Sciences*.**4**:721–729.

Niedergerke, R. (1956). ‘The potassium chloride contracture of the heart and its modification by calcium’, *Journal of Physiology*,**134**:584–599.

Noshad Q, and Anjum M (2018) Investigations of phytochemical and antifungal activity of *Carica papaya* L leaves. *Journal of Pure Applied Biology***7**(1): 309-314.

Obaro-onezeyi O.E. and Oshomoh E. O. (2019). Assessment of several concentrations of aqueous extracts of *Croton lobatus* Linn on reproductive parameters of female Wistar rats. *Journal of Science and Technology research* ,**1**(1): 72-80.

- Oshomoh E.O and Obaro-Onezeyi O.E (2020). Effect of *Talinum triangulare* on reproductive parameters of female Wistar rats.
- Omale, J. and Ugwu, C. E. (2011). Comparative studies on the protein and mineral composition of some selected Nigerian Vegetables. *African Journal of food Science* Vol.5 (1): 22-25.
- Peter K, and Gandhi P (2017) Rediscovering the therapeutic potential of *Amaranthus* species: a review. *Egypt Journal Basic Applied Sciences*, 4:196–20
- Parni B, Verma Y (2019) Biochemical properties in peel, pulp and seeds of *Carica papaya*. *Plant Archives*. 14(1): 565-568. 35. Prasad CH, Srin
- Qing Q., Lu Zhu, L., Zheng, Qi., Hao, Wu., Jing, J., Qing, C., Liu, Ya., Fugui F., Yunsheng, Yunhai Li., Zhang, j. and Yinghui, L. (2019). Comparison of the pituitary gland transcriptome in pregnant and non-pregnant goats (*Capra hircus*), *Journal of Animal Science*, 64, (10): 420–430.
- Rang H.P., Dale M.M. Ritter J.M. and Flower R.J. (2007b). *Pharmacology*. Churchill Livingstone. Edinburgh, United Kingdom P. 740- 849.
- Roshan A, Verma NK, Gupta A (2019) A Brief Study on *Carica Papaya*- A Review. *International Journal of Current Trends in Pharmaceutical Research* 2(4): 541-550.

Shaw, N.D., Histed, S.N., Srouji, SS., Yang, J., Lee, H. and Hall JE. (2010). Estrogen negative feedback on gonadotropin secretion: evidence for a direct pituitary effect in women. *Journal of Clinical Endocrinology and Metabolism*,**95**(4):195-199.

Sharma DK, Tiwari B, Singh RK, Sahu S, Mathur SC, et al. (2019) Estimation of Minerals in Carica papaya L. Leaf found in Northern India by using ICP-OES Technique. *International Journal of Scientific Engineering Research***4**(6): 1012. 24.

Yogiraj V, Goyal PK, Chauhan CS, Goyal A, Vyas B (2014) Carica papaya Linn: An Overview. *International Journal Herbal Medicine***2**(5): 1-8. 1

Yeap, S. K., Ho, W. Y., Beh, B. K., Liang, W. S., Ky, H., Hadi, A. and Alitheen, N. B. (2020). Vernonia amygdalina, an Ethnomedical used Green Vegetable with Multiple Bio-activities. *Journal of Medicinal Plants Research*,**4**(25): 2787–2812.

## Appendix 1

<b>Treatment mg/kg</b>	<b>Testosterone</b>	<b>Testosterone</b>	<b>Testosterone</b>	<b>Testosterone</b>	<b>Testosterone</b>	<b>Testosterone</b>
<b>control</b>	20.9	24.0	29.0	20.7	23.6	21.2
<b>Vercarim30</b>	9.7	10	9.9	10.2	9.8	9.9
<b>Vercarim60</b>	5.9	6.4	6.0	6.3	6.0	6.2
<b>Vercarim120</b>	8.4	8.8	9.8	9.9	10	9.0

Appendix 2

<b>Treatment</b>	<b>LH</b>	<b>LH</b>	<b>LH</b>	<b>LH</b>	<b>LH</b>	<b>LH</b>
<b>mg/kg</b>						
<b>control</b>	25	24.5	27.4	26.7	26.0	25.9
<b>Vercarim30</b>	0.9	1.0	1.9	1.2	1.3	1.1
<b>Vercarim60</b>	0.1	0.2	0.1	0.9	0.1	0.9
<b>Vercarim120</b>	0.4	0.4	0.6	0.5	0.8	0.7

### Appendix 3

<b>Treatment mg/kg</b>	<b>FSH</b>	<b>FSH</b>	<b>FSH</b>	<b>FSH</b>	<b>FSH</b>	<b>FSH</b>
<b>control</b>	22.0	22.0	24.9	27.0	28.0	24.0
<b>Vercarim30</b>	0.2	0.4	0.6	0.2	0.2	0.2
<b>Vercarim60</b>	0.2	0.2	0.2	0.2	0.2	0.2
<b>Vercarim120</b>	0.1	0.1	0.1	0.1	0.1	0.1